

## Original Article

Comprehensive assessment of the effect of *Sphenocentrum jollyanum* root extract on male reproductive activity in albino ratsYINUSA RAJI,<sup>1\*</sup> OLAYEMI O. FADARE,<sup>1</sup> RAHMAT A. ADISA<sup>2</sup> and SHAKIRU A. SALAMI<sup>1</sup>Departments of <sup>1</sup>Physiology and <sup>2</sup>Biochemistry, College of Medicine, University of Ibadan, Ibadan, Nigeria

**Aim:** To evaluate the effect of methanol extract from the *Sphenocentrum jollyanum* root on male reproductive activity.

**Methods:** Male albino rats were treated orally with distilled water (vehicle for the extract; control) and 50, 100 and 150 mg kg<sup>-1</sup> body weight of *Sphenocentrum jollyanum* root extract for 8 weeks. Each group had its own recovery. Rats were killed 24 h after the last treatment. Caudal epididymal sperm count, motility, viability, morphology and organ weights were determined. Hematological indices, serum proteins, enzymes, testicular superoxide dismutase (SOD) activity, and testicular and epididymal histology were determined.

**Results:** Compared with the control, the extract caused a dose dependent significant ( $P < 0.05$ ) reduction in progressive motility of spermatozoa, viability and total sperm counts. The number of abnormal spermatozoa and epididymal volume were not statistically significant. There was a significant increase ( $P < 0.05$ ) in serum testosterone levels in rats treated with 50 ( $P < 0.01$ ) and 100 mg kg<sup>-1</sup> ( $P < 0.05$ ) of *Sphenocentrum jollyanum*. There was a significant ( $P < 0.05$ ) increase in red blood cell count, packed cell volume and hemoglobin concentration, whereas there was no change in white blood cell count, mean

total serum protein, albumin and globulin in the sera of *Sphenocentrum jollyanum* treated rats when compared with the control. The extract caused a significant decrease ( $P < 0.05$ ) in serum aspartate and alanine aminotransferase activities with a significant increase ( $P < 0.05$ ) in testicular SOD activity at a dose of 50 mg kg<sup>-1</sup> bodyweight. Testicular cytoarchitecture of the extract treated rats showed degeneration of seminiferous tubules, whereas regeneration of germinal epithelium and restructuring of the germinal interstitium occurred in the recovery rats. No lesions were observed in the epididymis of the rats.

**Conclusion:** The results suggest that methanol extract of the *Sphenocentrum jollyanum* root could produce harmful effects on reproductive functions in male albino rats which can be attributed to poor sperm quantity (epididymal sperm count), quality (sperm motility, viability and morphology) and testicular degeneration. The steroidogenic potential of the plant could explain its use as an aphrodisiac agent. (Reprod Med Biol 2006; 5: 283–292)

**Key words:** albino rat, antimicrobial, male reproduction, *Sphenocentrum jollyanum*.

## INTRODUCTION

PLANTS HAVE BEEN used worldwide for treatment of various human ailments since ancient times. The use of medicinal plants in folkloric medicine is still prevalent in developing countries.<sup>1</sup> Many plant species from tropical forests have been identified as containing fertility enhancing and contraceptive compounds. About 370 of the plants have shown to offer promise of safer and more effective male and female contraceptive

agents. In addition, more than 600 plant species appear to offer potential as abortifacients.<sup>2</sup>

*Sphenocentrum jollyanum* is an erect shrub found in dense forest. The plant grows up to 1.5 m in height and has very few branches. *Sphenocentrum jollyanum* belongs to the *Menispermaceae* family of plants, which is composed primarily of lianas, and is dioecious with small inconspicuous flowers. The family is characterized by curved endocarps, which is reflected in its common name 'the moonseed family'.<sup>3</sup> It is believed by the traditional medicine practitioners of the Ivory Coast to have unusual hemostatic and stomachic properties. In addition, the root extract is ingested to relieve constipation and to increase appetite in southern Nigeria and Ghana.<sup>3</sup> The stem bark is valued as an aphrodisiac and general

\*Correspondence: Dr Yinusa Raji, Department of Physiology, College of Medicine, University of Ibadan, Ibadan, Nigeria.

Email: y.rajai@mail.ui.edu.ng

Received 29 June 2006; accepted 21 August 2006.

tonic, especially in Igboland of Southern Nigeria.<sup>4</sup> Decoctions prepared from the fruits, together with the fruits of *Piper guineense* and lime juice, are known to be effective in relieving cough. The fruits are also used as an antifatigue snack.<sup>3</sup> The plant is reputed as a wound healing agent in traditional medicine.<sup>3</sup> *Sphenocentrum jollyanum* yields several isoquinoline alkaloids, including palmatine, columbamine and bitter tasting diterpenes.<sup>4</sup>

Apart from its aphrodisiac action, which had been based on folklore, there is no information in the literature on the effect of *Sphenocentrum jollyanum* on male reproductive function. The present study was, therefore, aimed at evaluating the reproductive activities of *Sphenocentrum jollyanum* root extract in male albino rats.

## MATERIALS AND METHODS

### Plant material

THE ROOT OF *Sphenocentrum jollyanum* was collected at Oniganbari village via Ibadan Nigeria. The specimen was examined and identified by Mr Usang Felix Inah of Forest Research Institute of Nigeria (FRIN) Ibadan, Nigeria, where a voucher specimen (No 106994) was deposited.

### Preparation of extract

N-hexane and absolute methanol extraction of *Sphenocentrum jollyanum* root was carried out using an aspirator connected with its accessories.<sup>5</sup> Polar solvent, such as methanol and N-hexane, yielded more bioactive components during extraction. The aspirator with a reflux condenser and a dry distillation flask was set up. Powdered sample (2.75 kg) of the air-dried plant material was poured into the aspirator bottle with the extraction solvent to which the condenser was tightly connected. The set up was placed in a water bath and a heat regulator was adjusted so that the solvent boiled gently at 68°C. The solvent and the extracted molecules were siphoned until the extraction was completed. The extracted material was then separated from the solution by distillation. The processed residue yielded 1.3% yellow crude extract and was stored in the refrigerator from which fresh solution was prepared in distilled water when required.

### Animals

Male wistar strain albino rats (200–240 g, initial weight) were used for the study. The animals were housed in wire mesh cages at the Central Animal House, College of

Medicine, University of Ibadan, Ibadan Nigeria. The animals were allowed to acclimatize to laboratory conditions (12 h day/12 h night; 23 ± 3°C) for 2 weeks before commencement of the study. Food and water were provided ad libitum.

### Experimental design

Thirty-five male rats were divided into seven equal groups. Group I served as the control and the rats were given distilled water (vehicle for the extract). Groups II, III and IV rats were given 50, 100 and 150 mg kg<sup>-1</sup>, respectively, of *Sphenocentrum jollyanum* root extract. The vehicle and extract were given orally for 8 weeks. Each extract treated group had its corresponding recovery group from which treatment was withdrawn for 1 week before killing the rats. Rats were killed 24 h after the last extract or vehicle treatment. Samples for data collection were taken from each rat immediately.

### Blood samples

Blood was collected immediately after killing the animals by cardiac puncture into heparinized bottles for hematological parameters and plain bottles for hormone, enzyme and other biochemical assays (Mono International, Surulere, Lagos, Nigeria).

### Semen collection

The left testis was removed along with its epididymis. The caudal epididymis was separated from the testis and lacerated to collect semen with a microscope slide for sperm characteristic evaluation as previously described.<sup>6</sup>

### Semen characteristics analysis

Semen was squeezed on the slide and two drops of warm 2.9% sodium citrate were added. The slide was covered with a cover slip and examined under the microscope using ×400 magnification. Sperm viability was evaluated using the eosin–nigrosin stain. Semen was transferred to the slide and two drops of the stain were added. A thick smear was made and dried. The stained slide was examined under the microscope using ×400 magnification. The motile (live) sperm cells were unstained while the non-motile (dead) sperm absorbed the stain. The stained and unstained sperm were counted and the percentage of each was calculated. Sperm morphology was carried out with Walls and Ewas stain. Briefly, a smear was made, dried, stained with Walls

and Ewas stain, and examined under the microscope using  $\times 100$  magnification under oil immersion. About 400 sperm cells were counted and the average was taken for each abnormality. The epididymis from the right side was immersed in 5 mL normal saline in a measuring cylinder and the volume of fluid displaced was taken as the volume of the epididymis. The epididymis and 5 mL normal saline were then poured into a mortar and homogenized into a suspension from which a sperm count was carried out. The sperm count was carried out under the microscope using improved Neubauer hemocytometer.

### Hematological studies

Blood samples obtained immediately after killing the animals were analyzed for packed cell volume (PCV), hemoglobin levels (Hb), red blood cell counts (RBC) and white blood cell counts (WBC) as previously described.<sup>7</sup> Packed cell volume was determined by the microhematocrit technique using a Hawksley microhematocrit centrifuge and spinning for 5 min at  $12\,000 \times g$  before reading with the hematocrit reader. Heparinized capillary tubes were products of the British Drug House (Poole, UK). Hemoglobin levels were measured by the cyanmethemoglobin method using a CE 404 colorimeter (Cecil Instruments, Cambridge, UK.). The red blood cell and white blood cell counts were carried out using the hemocytometer method.

### Serum protein analysis

The biuret method was used for serum protein measurement. Approximately 0.01 mL of serum was added to 2.90 mL of distilled water to which 3 mL of working biuret was added. The protein concentration was estimated using Gallenkamp colorimeter (GallenKamp and Sons, London, UK) capable of measuring optical density at 550 nm and 492 nm.

### Measurement of serum alanine and aspartate aminotransferases activities

Serum (0.1 mL) was added into sample test tubes while 0.1 mL of distilled water was pipetted into a reagent blank test tube. Buffer (0.5 mL) was added to each test tube. The buffer was made up of phosphate buffer (100 mmol/L, pH 7.4), L-alanine (200 mmol/L) and  $\alpha$ -oxoglutarate (2.0 mmol/L) for the measurement of alanine aminotransferase (ALT) while L-aspartate (100 mmol/L) was used in place of L-alanine for the

measurement of aspartate aminotransferases (AST). The solution was mixed and incubated in a water bath for 30 min at 37°C. Approximately 0.5 mL of 2,4-dinitrophenylhydrazine was added, mixed and allowed to stand for 20 min at room temperature. Sodium hydroxide was added and the absorbance of each sample against the reagent blank was read at a wavelength of 546 nm after 5 min.

### Determination of superoxide dismutase

Superoxide dismutase (SOD) activity was evaluated using the RANSOD Kit (Randox, Crumlin, England), with one modification. Instead of whole blood samples, homogenized and filtered testis solution was used. The kit contained mixed substrate (xanthine, 0.05 mmol/L and I.N.T. 0.05 mmol/L), buffer (CAPS 40.00 mmol/L, pH 10.2, EDTA, 0.94 mmol/L), xanthine oxidase standard (80 U/L), sample diluents (5.40 U/L) and phosphate buffer (0.01 mol/L, pH 7.0) (50.00 mL of 0.20 mol  $\text{KH}_2\text{PO}_4$  + 29.65 mL of 0.20 N NaOH made up to 1 L, with distilled water). The percentage inhibition of each sample was used to obtain the SOD units from a standard curve of the reconstituted and diluted RANSOD kit.

### Estimation of serum levels of testosterone

Serum testosterone concentrations were estimated using the Enzyme Immunology Assay (EIA) method as earlier described.<sup>8–11</sup> Collected serum samples were stored at  $-20^\circ\text{C}$  until assayed. Used EIA kits were obtained from Immunometrics (London, UK), and contained testosterone EIA substrate reagents and EIA quality control samples. A quality control sample was run for the hormone at the beginning and at the end of the assay to ascertain acceptability with respect to bias and within assay variation. Used EIA kits had a sensitivity level of 0.3 nmol/L (0.1 g/mL). The intra and inter assay variations were 11.00% and 10.10%, respectively.

### Histology

Testes and epididymides of control and extract treated rats were fixed in Bouin's fluid for 6 h before they were transferred into 10% formalin for histological evaluation.<sup>9</sup> The tissues were placed in 50, 70, 90, 95% and then absolute alcohol for about 2 h in each of the alcohol preparations. The tissues were then infiltrated twice with xylene for about 2 h each time before placed in a molten wax twice for about 2 h at a constant temperature of 56–60°C in an oven. After the paraffin has cooled, it

**Table 1** Effect of methanol extract of the *Sphenocentrum jollyanum* root on body and organ weight in male albino rats

Dose of <i>S. jollyanum</i> (mg/kgd)	Bodyweight (g)	Testis (g)	Epididymis (g)	Liver (g)
0 (Control)	208 ± 8.0	1.26 ± 0.04	0.44 ± 0.02	3.30 ± 0.41
50	220 ± 6.3 (208 ± 4.9)	1.54 ± 0.05* (1.47 ± 0.06*)	0.45 ± 0.02 (0.45 ± 0.03)	3.31 ± 0.37 (3.30 ± 0.40)
100	224 ± 16.7 (238 ± 4.4)	1.55 ± 0.06* (1.36 ± 0.05)	0.43 ± 0.01 (0.44 ± 0.02)	3.32 ± 0.39 (3.30 ± 0.40)
150	256 ± 7.6 (252 ± 6.6)	1.30 ± 0.05 (1.28 ± 0.06)	0.44 ± 0.02 (0.45 ± 0.03)	3.35 ± 0.41 (3.34 ± 0.40)

\* $P < 0.05$  compared with the control. Recovery values are in parenthesis.  $n = 5$ .

was immersed in water, solidified and the metal blocks were removed. The sections were cut (5–15  $\mu$ ) using a rotary microtome. One surface of a slide was made adhesive by rubbing it with a drop of egg albumen. A tissue section was then placed in the center of the slide and immersed in a water bath (50–55°C). Water was drained and the slide was placed in an incubator at 37–40°C overnight. Each section was deparaffinized in xylene for 1 min before immersed in absolute alcohol for about 1 min and later in descending concentrations of alcohol, for about 30 s each, to hydrate it. The slide was then rinsed in water and immersed in aqueous solution of hematoxylin for about 10 min until the color of the section became blue. The slide was dipped in 1% aqueous eosin for 30 s and rinsed in water for a few seconds, before being immersed in 70%, 90% and twice in absolute alcohol for 30 s each to dehydrate the preparation. The preparation was cleared of alcohol by dipping it in xylene for 1 min. Each slide was then cleaned, blotted and mounted in Canada balsam under a cover slip and examined under the microscope ( $\times 250$  magnification). Photomicrographs of the slide preparation were then taken.

### Statistical analysis

Results were expressed as mean  $\pm$  SEM, and were analyzed using Student's *t*-test and ANOVA. The level of significance was accepted at  $P < 0.05$ .

## RESULTS

### Effect of methanol extract of *Sphenocentrum jollyanum* root on body and organ weight of male albino rats

THERE WAS NO change in bodyweight, whereas there was a significant ( $P < 0.05$ ) increase in the

testis weight of the *Sphenocentrum jollyanum* treated rats when compared with their control counterparts. There was also no change in liver and epididymal weight when compared with their respective control groups. However, there was a significant ( $P < 0.05$ ) recovery in these parameters when the treatment was withdrawn (Table 1).

### Semen analysis

There was a dose dependent significant ( $P < 0.01$ ) reduction in the percentage of progressive sperm motility, sperm counts and viability of *Sphenocentrum jollyanum* extract treated rats. There was a significant improvement in these parameters in recovery experiments. There was no significant difference in epididymal volume in all the groups when compared with control. There was also a significant increase ( $P < 0.05$ ) in the total number of abnormal spermatozoa in the treated groups when compared with their control counterpart (Table 2).

### Serum testosterone level

There was a significant ( $P < 0.01$ ) increase in serum testosterone level in rats treated with 50 mg kg<sup>-1</sup> of *Sphenocentrum jollyanum* extract. This level decreased with increasing doses of the extract. However, the serum testosterone level in the recovery groups returned to the control value within 1 week of extract withdrawal (Table 3).

### Hematological parameters

There was a significant increase ( $P < 0.05$ ) in packed cell volume, red blood cell count and hemoglobin concentration in 50 mg kg<sup>-1</sup> of the extract treated group when compared with the control group. There was no significant change in white blood cell count in the extract treated rats compared with the control (Table 4).

**Table 2** Effect of *Sphenocentrum jollyanum* root extract on semen characteristics of rats

Dose of <i>S. jollyanum</i> (mg/kgd)	% Progressive motility	% Viability	Epididymal volume (ml)	Sperm count $\times 10^6$ /mL	% Abnormal sperm
0 (control)	91 $\pm$ 1.00	96.8 $\pm$ 0.73	5.18 $\pm$ 0.005	83.6 $\pm$ 3.51	5.9 $\pm$ 0.29
50	55 $\pm$ 2.58* (76 $\pm$ 5.0)	57.5 $\pm$ 1.29 (64.0 $\pm$ 4.0)	5.17 $\pm$ 0.020 (5.14 $\pm$ 0.024)	52.0 $\pm$ 4.11* (62.4 $\pm$ 3.88)	27.93 $\pm$ 2.64** (7.95 $\pm$ 1.24)
100	74 $\pm$ 6.78 (76 $\pm$ 2.44)	67.0 $\pm$ 4.63 (72.0 $\pm$ 2.00)	5.16 $\pm$ 0.020 (5.18 $\pm$ 0.020)	67.8 $\pm$ 5.73* (67.6 $\pm$ 3.85)	22.85 $\pm$ 3.32* (6.8 $\pm$ 1.48)
150	56 $\pm$ 2.44* (74 $\pm$ 4.00)	79.0 $\pm$ 2.44 (82.0 $\pm$ 3.39)	5.18 $\pm$ 0.020 (5.16 $\pm$ 0.024)	58.8 $\pm$ 2.57* (58.0 $\pm$ 2.64)	21.35 $\pm$ 3.35* (7.0 $\pm$ 2.53)

Recovery values are in parentheses. \*Significantly reduced ( $P < 0.05$ ) and \*\*increased ( $P < 0.01$ ) compared with the control.

**Table 3** Effect of methanol extract of *Sphenocentrum jollyanum* root on serum testosterone level

Dose of <i>S. jollyanum</i> (mg/kgd)	Testosterone level (nmol/L)
0 (Control)	0.52 $\pm$ 0.00
50	3.90 $\pm$ 0.30* (0.62 $\pm$ 0.00)
100	1.10 $\pm$ 0.30* (0.60 $\pm$ 0.00)
150	0.60 $\pm$ 0.00 (0.54 $\pm$ 0.00)

Values in parentheses were for recovery. \*Significantly higher than the control ( $P < 0.05$ );  $n = 5$ .

### Serum protein

There was no significant difference ( $P > 0.05$ ) in mean serum total protein, albumin and globulin in the *Sphenocentrum jollyanum* extract treated rats when compared with the control group (Table 5).

### Serum enzymes

There was a slight decrease in the activity of AST and ALT in all the treated groups when compared with the control group (Table 5). However, the extract significantly ( $P < 0.05$ ) caused an increase in superoxide dismutase (SOD) activities at a low dose (50 mg kg<sup>-1</sup>), but appeared to produce no further increase in this parameter at higher doses. These effects were reversible.

### Histology of the testis and epididymis

There were many degenerated seminiferous tubules in the testis of the extract treated rats. The lumen of the epididymis contained few immature sperm cells. However, significant regeneration of the seminiferous tubule of the germinal epithelium and restructuring of the interstitium with significant increase in sperm cells in the lumen of the epididymis were observed in the recovery group (Table 6, Figs 1 and 2).

### DISCUSSION

THE RESULTS OF the present study suggest that methanol extract of the *Sphenocentrum jollyanum*

**Table 4** Mean hematological values of male rats treated with *Sphenocentrum jollyanum* root extract

Dose of <i>S. jollyanum</i> (mg/kgd)	PCV (%)	RBC $\times 10^6$ /mm <sup>3</sup>	Hb g/100 mL	WBC $\times 10^3$ /mm <sup>3</sup>
0 (Control)	43.2 $\pm$ 3.30	8.76 $\pm$ 1.49	12.7 $\pm$ 1.07	12.08 $\pm$ 3.25
50	47.6 $\pm$ 1.56* (43.8 $\pm$ 1.24)	9.98 $\pm$ 0.99* (7.32 $\pm$ 1.09)	13.8 $\pm$ 0.39* (12.90 $\pm$ 0.53)	12.44 $\pm$ 3.90 (11.32 $\pm$ 1.96)
100	40.2 $\pm$ 3.84 (44.2 $\pm$ 7.51)	8.01 $\pm$ 0.67 (7.37 $\pm$ 1.50)	12.88 $\pm$ 0.81 (11.04 $\pm$ 0.57)	11.44 $\pm$ 1.09 (10.64 $\pm$ 0.88)
150	40.8 $\pm$ 3.33 (40.7 $\pm$ 3.38)	7.91 $\pm$ 0.84 (7.47 $\pm$ 1.10)	12.92 $\pm$ 0.52 (11.72 $\pm$ 0.40)	10.72 $\pm$ 2.04 (10.48 $\pm$ 4.01)

Hb, hemoglobin concentration; PCV, packed cell volume; RBC, red blood cell count; WBC, white blood cell count. Values in parentheses were for recovery. \*Significantly higher than the control ( $P < 0.05$ ).  $n = 5$ .

**Table 5** Effect of methanol extract of the *Sphenocentrum jollyanum* root on serum proteins and enzymes

Dose of <i>S. jollyanum</i> (mg/kgd)	Total protein mg/dL	Albumin mg/dL	Globulin mg/dL	AST ( $\mu\text{mol/ h/mg Protein}$ )	ALT ( $\mu\text{mol/ h/mg Protein}$ )	SOD (SOD units/mL)
0 (Control)	5.98 $\pm$ 0.70	1.98 $\pm$ 0.23	4.00 $\pm$ 0.48	504.6 $\pm$ 201.16	349.2 $\pm$ 33.51	2.05 $\pm$ 0.24
50	6.12 $\pm$ 0.15 (6.08 $\pm$ 0.82)	2.00 $\pm$ 0.07 (1.88 $\pm$ 0.33)	4.62 $\pm$ 0.08 (4.30 $\pm$ 0.49)	484.25 $\pm$ 55.14 (443.30 $\pm$ 0.49)	314.5 $\pm$ 28.31 (320.0 $\pm$ 34.92)	3.01 $\pm$ 0.28 (2.16 $\pm$ 0.26)
100	6.81 $\pm$ 0.06 (5.97 $\pm$ 0.41)	2.06 $\pm$ 0.06 (2.05 $\pm$ 0.14)	4.34 $\pm$ 0.19 (4.17 $\pm$ 0.50)	429.6 $\pm$ 112.10 (428.5 $\pm$ 15.19)	312.2 $\pm$ 22.79 (333.4 $\pm$ 31.09)	2.11 $\pm$ 0.30 (2.10 $\pm$ 0.27)
150	6.06 $\pm$ 1.08 (6.04 $\pm$ 0.35)	1.78 $\pm$ 0.31 (1.82 $\pm$ 0.13)	4.02 $\pm$ 0.76 (4.01 $\pm$ 0.21)	440.5 $\pm$ 45.24 (464.25 $\pm$ 60.77)	330.7 $\pm$ 17.82 (340.5 $\pm$ 3.36)	2.10 $\pm$ 0.29 (2.03 $\pm$ 0.28)

ALT, alanine aminotransferase; AST, aspartate aminotransferase; SOD, superoxide dismutase. Values in parentheses were for recovery.  $n = 5$ .

**Table 6** Effect of methanol extract of the *Sphenocentrum jollyanum* root on the histology of the testis and epididymis of male albino rats

Dose of <i>S. jollyanum</i> (mg/kgd)	Testicular architecture	Epididymal architecture
0 (Control)	---	---
50	+++ (+)	--- (---)
100	+ (-)	--- (---)
150	+ (--)	--- (---)

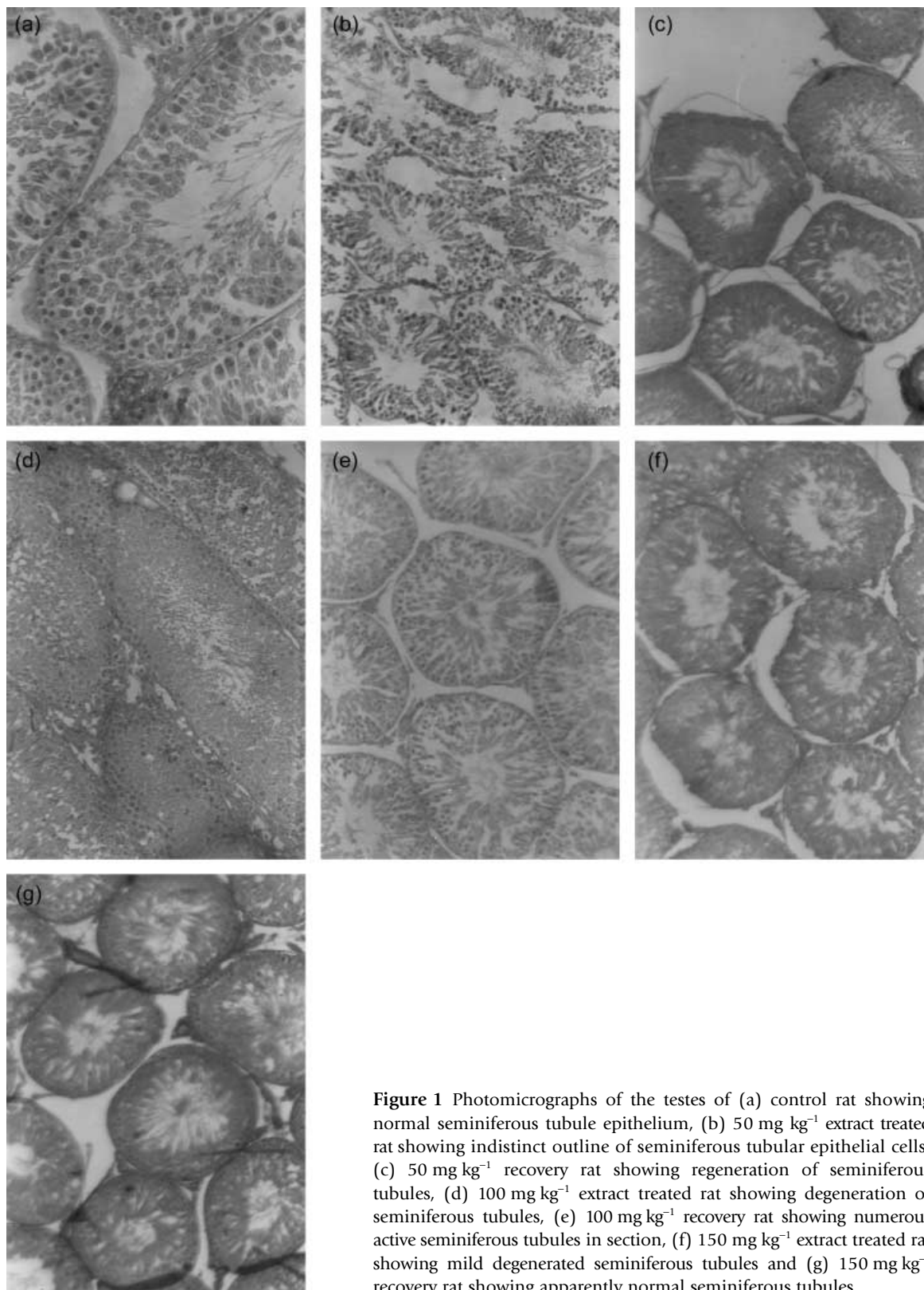
+ = Mild; ++ = moderately severe; +++ = severe, degeneration of the seminiferous tubule of the testis; - = mild lesion; -- little or no lesion; ---, no lesion at all in the histology of the tissue.

root could be harmful to reproductive function of male albino rats as a marked reduction in sperm quality and quantity were observed. The histological study showed degenerated seminiferous tubules and immature sperm cells in the epididymal lumen. However, the extract seemed to improve the overall quality of blood and serum proteins at a low dose. Most of the reproductive and biochemical changes induced by the extract occurred at the low dose used in the present study. The LD<sub>50</sub> of *Sphenocentrum jollyanum* root extract in mice was found to be 136.5 mg kg<sup>-1</sup>. The slight decrease in ALT and AST activities could suggest a significant level of safety of the plant extract. There was an increase in serum testosterone level at low and medium doses used in the present study. The deleterious effects of the extract on

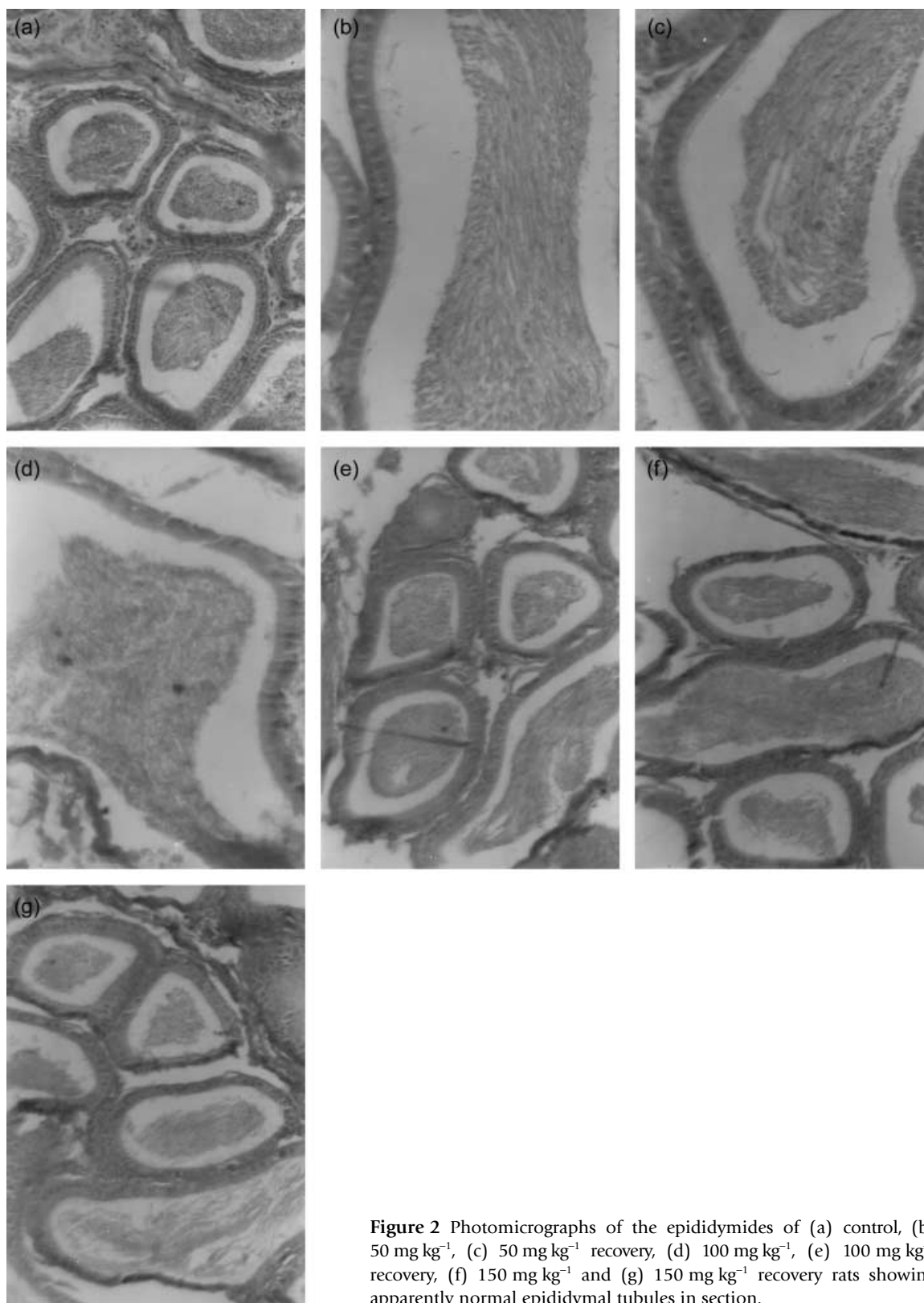
sperm quality and testicular morphology were, however, reversible in the present study.

Defective sperm function is the most prevalent cause of male infertility<sup>12</sup> and reactive oxygen species (ROS) are known to be important mediators of sperm function.<sup>13</sup> ROS are produced by a variety of semen components including immotile or morphologically abnormal spermatozoa, leukocytes and morphologically normal but functionally abnormal spermatozoa.<sup>14</sup> Although antioxidant activity of *Sphenocentrum jollyanum* was not determined in the present study, earlier work has shown that the plant has potent antioxidant action. Oke and Hamburger<sup>15</sup> reported the presence of antioxidant activity in *Sphenocentrum jollyanum*. It is known that oxygen-handling cells have antioxidants SOD and catalase that act synergistically for the complete detoxification of superoxide and hydrogen peroxide.<sup>16</sup> The significant increase in testicular SOD activity in the present study corroborates the findings of earlier workers<sup>15</sup> and could be responsible for certain beneficial effects of *Sphenocentrum jollyanum* in traditional medicine.

The phytochemical screening of *Sphenocentrum jollyanum* showed the presence of tannins and saponins. The plant also yields several isoquinoline alkaloids, including palmatine and columbamine.<sup>4</sup> Alkaloids are compounds that form salts with acids. They contain nitrogen and generally in heterocyclic and/or ring structure. Quinoline and isoquinoline alkaloids are a heterogeneous group of alkaloids with known toxicity to humans and domestic animals.<sup>17</sup> The toxic effect of *Sphenocentrum jollyanum* on some aspects of male reproduction might be as a result of activity of isoquinoline, because many alkaloids have varying degrees of neurological effects ranging from relaxation and euphoria to seizures. Alkaloids also cause vasodilation.<sup>17</sup> The observed effects of *Sphenocentrum*



**Figure 1** Photomicrographs of the testes of (a) control rat showing normal seminiferous tubule epithelium, (b) 50 mg kg<sup>-1</sup> extract treated rat showing indistinct outline of seminiferous tubular epithelial cells, (c) 50 mg kg<sup>-1</sup> recovery rat showing regeneration of seminiferous tubules, (d) 100 mg kg<sup>-1</sup> extract treated rat showing degeneration of seminiferous tubules, (e) 100 mg kg<sup>-1</sup> recovery rat showing numerous active seminiferous tubules in section, (f) 150 mg kg<sup>-1</sup> extract treated rat showing mild degenerated seminiferous tubules and (g) 150 mg kg<sup>-1</sup> recovery rat showing apparently normal seminiferous tubules.



**Figure 2** Photomicrographs of the epididymides of (a) control, (b)  $50 \text{ mg kg}^{-1}$ , (c)  $50 \text{ mg kg}^{-1}$  recovery, (d)  $100 \text{ mg kg}^{-1}$ , (e)  $100 \text{ mg kg}^{-1}$  recovery, (f)  $150 \text{ mg kg}^{-1}$  and (g)  $150 \text{ mg kg}^{-1}$  recovery rats showing apparently normal epididymal tubules in section.



*jollyanum*, especially on male reproductive parameters, might be similar to the negative impact of the extract of *Morinda lucida*,<sup>9</sup> *Azadirachta indica*,<sup>8</sup> *Ricinus communis*,<sup>10</sup> *Alstonia boonei*<sup>23</sup> and *Quassia amara*<sup>5,6,18</sup> on male reproductive parameters. The major constituent in these medicinal plants is alkaloid.

The enzymes investigated in the present study belong to the class of enzymes whose concentration in the blood can be used diagnostically to determine the level of dysfunction of the liver, kidneys and heart.<sup>19,20</sup> Unlike human serum, in which normal ranges of these enzymes have been established, those of most species of animals have not been determined.<sup>21</sup> The levels of enzyme activities in the *Sphenocentrum jollyanum* extract treated group were, therefore, compared with the vehicle treated control group. The slight decrease in the activity of serum aspartate and alanine aminotransferases activities in all the extract treated groups, as compared with their control counterpart, could be a result of the anti-angiogenic impact of *Sphenocentrum jollyanum* reported by Nia *et al.*<sup>22</sup> and might be similar to that of *Alstonia boonei*.<sup>23</sup> Angiogenesis or neo-vascularization is a multi-step process leading to the formation of new capillaries emerging from pre-existing blood vessel systems. Any imbalance in the control of this complex system might promote numerous angiogenesis dependent diseases.<sup>24</sup> Inhibition of angiogenesis is a prime target of afflictions such as the growth of solid tumors, arthritis and inflammation. This assumption could explain the efficacy of the plant as a wound healing agent against tumors<sup>4</sup> and is further supported by the results of hematological analysis in the present study.

Testosterone is secreted by the Leydig cells under luteinizing hormone (LH) stimulation and is essential for promoting spermatogenesis. LH and follicle stimulating hormone (FSH) are produced in the anterior pituitary gland and secreted episodically in response to the pulsatile release of gonadotrophin releasing hormone (GnRH).<sup>25</sup> The effects of prolonged GnRH agonist therapy are biphasic, consisting of an initial stimulatory phase, in which levels of serum FSH, LH and testosterone rise, followed by a downregulation of LH and FSH secretion with a concomitant lowering of testosterone.<sup>26</sup> The mechanism whereby GnRH agonist therapy stimulates spermatogenesis in models of injury, however, is poorly understood. It has been hypothesized that an elevation of intratesticular testosterone contributes to the maintenance of testicular atrophy and that agents reducing the intratesticular testosterone levels stimulate the recovery of spermatogenesis.<sup>25</sup> This hypothesis could be related to the result obtained in the present study where

there was an increase in the serum level of testosterone after administration of 50 mg kg<sup>-1</sup> body weight of the methanolic extract of the *Sphenocentrum jollyanum* root. This level however, reduced with the administration of higher doses of the extract. It is probable that steroidogenic potentiation was responsible for the use of *Sphenocentrum jollyanum* as an aphrodisiac in traditional medicine.<sup>4</sup> The histological result also showed a dose dependent degeneration of seminiferous tubules. The decrease in sperm count and high number of morphologically abnormal sperm also indicates interference with testicular spermatogenesis. The hormonal levels and cytoarchitecture of the testis were, however, restored to normal in the recovery groups. These results suggest that *Sphenocentrum jollyanum* root is a possible GnRH agonist that can abolish sperm production when administered exogenously.<sup>26</sup> Although GnRH stimulates production and release of LH and FSH, constant exposure to GnRH results in inhibition of gonadotrophins release and concomitant reduction in serum testosterone.

In conclusion, the results of the present study suggest that methanol extract from the *Sphenocentrum jollyanum* root has an antifertility effect that could be attributed to poor sperm quantity, quality and testicular degeneration. Methanol extract from the *Sphenocentrum jollyanum* root could increase the serum level of testosterone at a low dose, which might explain its use in traditional medicine as an aphrodisiac agent. Further studies in progress are expected to shed more light on the impact of *Sphenocentrum jollyanum* as an aphrodisiac agent and on fertility.

## REFERENCES

- 1 Murga R, Scrivstara S, Kulshreshta DK, Gupta CM. Traditional remedies for fertility regulation. *Current Medical Chemistry* 2004; **11**: 1431–1450.
- 2 World Health Organisation. Report of task force on antifertility plants especially from tropical forests. WHO Geneva, Switzerland, 1981.
- 3 Daziel JM. The useful plants of West Tropical Africa. Crown Agents, London, 1937; 264.
- 4 Iwu MM. Handbook of African Medicinal Plants. CRC Press, Boca Raton, 1993; 116–118.
- 5 Njar VCO, Alao TO, Okogun JI, Raji Y, Bolarinwa AF, Nduka EU. Antifertility activity of *Quassia amara*: Quassin inhibits the steroidogenesis in rats Leydig cells *in vitro*. *Planta medica* 1995; **61**: 180–182.
- 6 Raji Y, Bolarinwa AF. Antifertility activity of *Quassia amara* in male rats – *In Vivo* study. *Life sciences* 1997; **61**: 1067–1074.
- 7 Raji Y, Odukanmi A, Olaleye SB, Onasanwo SA, Salami SA,

- Bolarinwa AF, Quassin: The antianaemic principle of *Quassia amara* extract. *Pakist J Biol Sci* 2006 (in press).
- <sup>8</sup> Raji Y, Udoh US, Mewoyeka OO, Ononye FC, Bolarinwa AF. Implication of reproductive endocrine malfunction in male antifertility efficacy of *Azadirachta indica* extract in rats. *J Med Med Sci* 2003; **32**: 159–165.
- <sup>9</sup> Raji Y, Akinsomisoye OS, Salman TM. Antispermatozoic activities of *Morinda lucida* extract in male albino rats. *Asian Jour Andrology* 2005a; **7**: 405–410.
- <sup>10</sup> Raji Y, Oloyo AK, Morakinyo AO. Studies on the reproductive activities of methanol extract of *Ricinus communis* seed in male albino rats. *Asian Jour Andrology* 2006a; **8**: 115–121.
- <sup>11</sup> Raji Y, Awobajo FO, Kunle-Alabi OT, Gbadegesin MA, Bolarinwa AF. *In vivo* and *in vitro* reproductive toxicity assessment of ampicillin and cloxacillin in mammalian models. *Int Jour Pharmacolo* 2006b; **2**: 9–14.
- <sup>12</sup> Hull M, Glazener C, Kelly N, Conway D, Foster P, Hinton R. Population study of causes, treatment and outcome of infertility. *Br Med J* 1985; **291**: 1693–1697.
- <sup>13</sup> De Lamirande E, Gagnon C. Impact of reactive oxygen species on spermatozoa. A balancing act between beneficial and detrimental effects. *Hum Reprod* 1995; **10** (Suppl 1): 15–21.
- <sup>14</sup> Plante M, DeLamirande E, Gagnon C. Reactive oxygen species released by activated neutrophils, but not by deficient spermatozoa, are sufficient to affect normal sperm motility. *Fertile Steril* 1994; **62**: 387–393.
- <sup>15</sup> Oke JM, Hamburger MO. Screening of some Nigerian medicinal plants for antioxidant activity using 2,2-diphenylpicrylhydrazyl radical. *Afri Biome Res* 2002; **5**: 77–79.
- <sup>16</sup> Macmillan-Crow LA, Crow JP, Thompson JA. Peroxynitrate mediated inactivation of manganese SOD involves nitration and oxidation of critical tyrosine residues. *Biochemistry* 1980; **37**: 1613–1622.
- <sup>17</sup> Williams GD, Richard JH. Plant Poisoning Alkaloids—Isoquinoline and Quinoline. Michael SB et al., eds. *Emergency Medicine* Northeastern Ohio Universities College of Medicine, 2002.
- <sup>18</sup> Parveen S, Das S, Kundra CP, Pereira BMJ. A comprehensive evaluation of the reproductive toxicity of *Quassia amara* in male rats. *Reprod Toxicol* 2003; **17**: 45–50.
- <sup>19</sup> Bell GH, Davidson JN, Emslie-Smith J. *Textbook of Physiology and Biochemistry*, 8th edn. Churchill Livingstone Edinburgh and London, 1972: 117.
- <sup>20</sup> Sevelius E. Diagnosis and Prognosis of Chronic Hepatitis and Cirrhosis in Bucks. *Journ Small Anim Prac* 1995; **36**: 512–528.
- <sup>21</sup> Oyeyemi MO, Olaifa AK, Onwuka SK, Akinloye AK, Utho OA. The effects of bilateral orchidectomy on some serum enzymes and proteins in the West African Dwarf Buck. *Afri Jour Biome Res* 2000; **3**: 105–108.
- <sup>22</sup> Nia R, Paper DH, Essien EE et al. Evaluation of the anti-oxidant and anti-angiogenic effects of *Sphenocentrum Jollyanum* Pierre. *Afri Jour Biome Res* 2004; **7**: 129–132.
- <sup>23</sup> Raji Y, Salman TM, Akinsomisoye OS. Reproductive functions in male rats treated with methanolic extract of *Alstonia boonei* stem bark. *Afr Biomed Res* 2005b; **8** (2): 105–111.
- <sup>24</sup> Kasbauer CW, Paper DH, Franz G. Sulfated ( $\beta$ 1–4) galactooligosaccharide and their effects on angiogenesis. *Carbohydrate Res* 2001; **330**: 427–430.
- <sup>25</sup> Meistrich ML, Wilson G, Huhtaniemi I. Hormonal treatment after cytotoxic therapy stimulates recovery of spermatogenesis. *Cancer Res* 1999; **59**: 3557–3560.
- <sup>26</sup> Okada H, Doken Y, Ogana Y, Toguchi H. Sustained suppression of the pituitary–gonadal axis by leuprorelin three-month depot microspheres in rats and dogs. *Pharm Res* 1994; **11**: 1199–1203.