

See discussions, stats, and author profiles for this publication at: <https://www.researchgate.net/publication/349893249>

Pharmacological study of *Amarantus spinosus* L. roots

Conference Paper · November 2020

DOI: 10.3390/ECMC2020-07261

CITATIONS

0

READS

20

5 authors, including:



Kokou Atchou

Université de Lomé

8 PUBLICATIONS 24 CITATIONS

SEE PROFILE



Metowogo Kossi

Université de Lomé

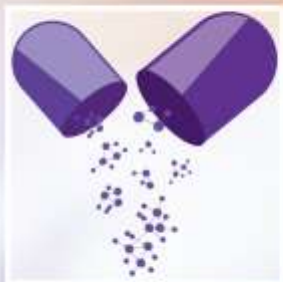52 PUBLICATIONS 358 CITATIONS

SEE PROFILE

Some of the authors of this publication are also working on these related projects:



Bioactives compounds valorization in treatment of non transmissible disease [View project](#)



6th International Electronic Conference on Medicinal Chemistry

1-30 November 2020

sciforum.net/conference/ECMC2020

sponsored by



pharmaceuticals

Pharmacological study of *Amaranthus spinosus* L. roots

**Kokou Atchou ^{1,*}, Povi Lawson-Evi ¹, Kossi Metowogo ¹, Kwashie Eklugadegbeku ¹
and Kodjo AkliKokou ¹**

¹ Laboratory of Physiology-Pharmacology, Unit of Pathophysiology, Bioactive Substances and Safety, Faculty of Sciences, University of Lome, Postbox 1515 Lome -Togo

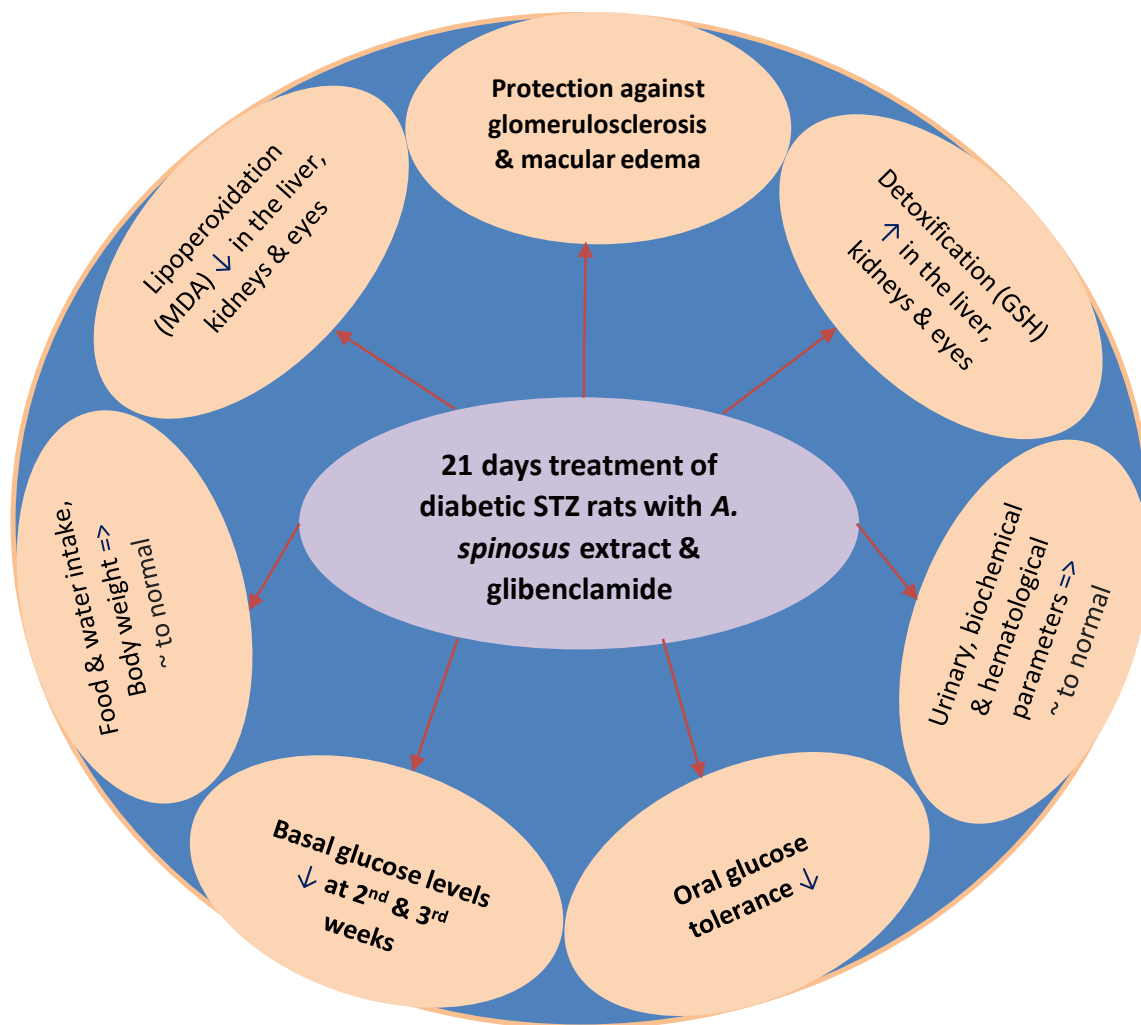
* Corresponding author: n.k.atchou@gmail.com



Université
de Lomé

Pharmacological study of *Amaranthus spinosus* L. roots

Graphical Abstract



Abstract:

Amaranthus spinosus is a medicinal plant used traditionally to treat diabetes mellitus. This study aimed to evaluate the antidiabetic activity of the plant in diabetic STZ rats. The antidiabetic activity of the hydroethanolic extract of the roots of *A. spinosus* was evaluated in diabetic STZ rats for 21 days. The results showed that *A. spinosus* extract 500 mg/kg b.w and glibenclamide used as reference drug caused a significant ($p < 0.0001$) decrease in oral glucose tolerance and basal blood glucose levels in diabetic STZ. At the end of treatment, food and water intake, body weight, urinary, biochemical and haematological parameters were significantly ($p < 0.0001$) returned to normal in the treated groups. In the liver, kidneys and eyes, a significant decrease ($p < 0.0001$) in MDA and an increase in GSH was observed in treated rats. Histopathological studies of the kidneys and eyes revealed no damage in rats treated with extract of *A. spinosus* and glibenclamide in contrast to glomerulosclerosis and macular edema seen in untreated groups. These results show that *A. spinosus* roots has bioactive compounds and the extract 500 mg/kg b.w can be administered orally to treat type II diabetes and its complications related to oxidative stress.

Keywords: Bioactive compounds; diabetes; biochemical; hamatological parameters; histopathological studies.



Diabeties :

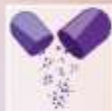- ⇒ **Metabolic disease**
 - Affects people of all ages
 - In all geographic regions of the world
 - Evolution ↑
- ⇒ **Global prevalence**
 - 2019 => 9.3% or 463 million adults
 - 2030 => 10.2% & 2045 => 10.6% (IDF, 2019)
 - death => 1 person every second
- ⇒ **Diagnosis**
 - Fasting blood glucose ≥ 7.0 mmol/L (ADA, 2020)
 - blood glucose ≥ 11.1 mmol/L after OGTT



Diabeties :

⇒ Classification:

- T1DM (5-10%), common in children and young people, result in a gradual loss of β cells by an autoimmune process leading to insulin deficiency
- T2DM (90-95%) typically seen in adults, result from a decrease in the sensitivity of insulin receptors to insulin and dysfunction of β cells leading to insulin resistance and insulinopenia
- GDM estimated at 15.8% of live births in women due to the resistance of cells to the action of insulin towards the end of the 2nd and 3rd trimester of pregnancy
- Other types of diabetes due to various causes (ADA, 2020)



Diabeties

⇒ **Symptoms:** polyuria; polydipsia; body weight loss & blurred vision

⇒ **Complications :**

- Infection & inflammation
- Metabolic complications : hypoglycemia; Ketoacidosis & hyperosmolar coma; oxidative stress (**Wachtel et al., 1991: Giacco & Brownlee, 2010**)
- Neurodegenerative complications :
 - ✓ Macroangiopathies : atherosclerosis; myocardial infarction, stroke
 - ✓ Microangiopathies: blindness and kidney failure (**IDF, 2019**)

⇒ **Prevention :** diet, physical exercise (in T2DM)

⇒ **Treatment :** T1DM: insulin & other alternatives.

T2DM: oral antidiabetics & insulin if needed



Medicinal plants are used as oral antidiabetics to treat T2DM and have insulin-sensitizing or insulin-secreting or insulin-modulating actions. *A. spinosus* is one of the medicinal plants whose roots are used in traditional medicine to treat diabetes.



Amaranthus spinosus L.

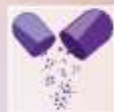

Aim of study

Evaluate the antidiabetic activity of *Amaranthus spinosus* in diabetic STZ rats

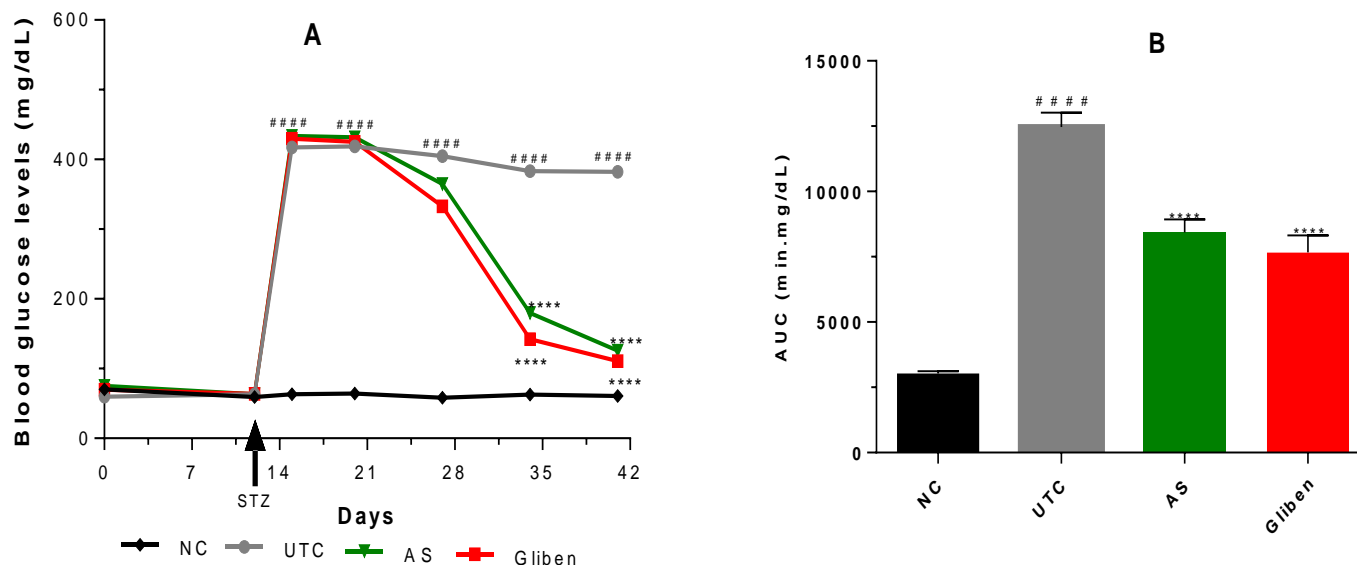
Objectives

- Induce diabetes & complications in Sprague Dawley rats treated with fructose-lard for 20 days
- Treat diabetes rats with *A. spinosus* for 21 days
- Measure blood glucose levels in diabetes rats before and weekly during the experimental
- Evaluate urinary, biochemical, hematological and histopathology parameters at the start and at the end of treatment.



Results and discussion

Effect of *A. spinosus* on basal glucose levels



Injection of STZ at 12th days \Rightarrow \uparrow blood glucose levels ($p < 0.0001$). Treatment with *A. spinosus* 500 mg/kg (AS) & glibenclamide 0.6 mg/kg (Gliben) \Rightarrow \downarrow in blood glucose levels ($p < 0.0001$) at 2nd (D35) and 3rd (D41) compared to UTC (Figure A). The area under the curve confirmed this \downarrow in blood glucose levels ($p < 0.0001$) (Figure B).



Effect of *A. spinosus* on glucose intolerance

Diabetes rats were submitted to OGTT at the end of 21 days of treatment.

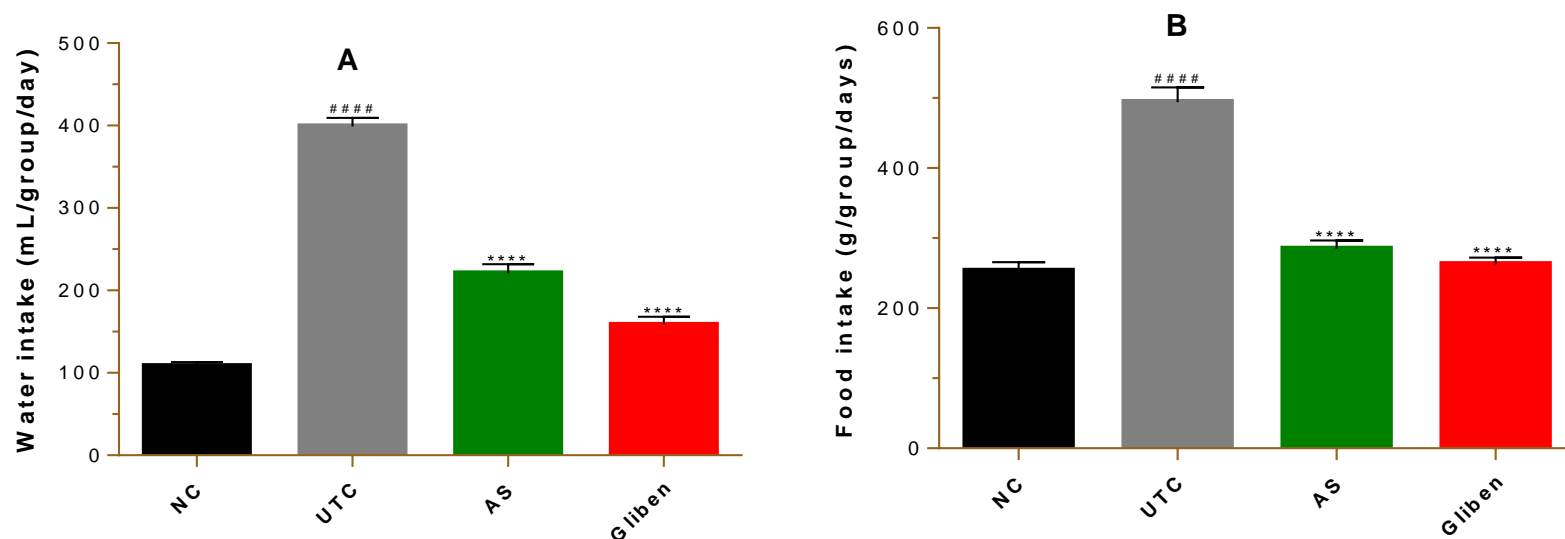
After 2 g/kg of glucose overload in diabetes rats prior fasted, the treatment with *A. spinosus* 500 mg/kg & glibenclamide 0.6 mg/kg :

⇒ ↓ in blood glucose levels ($p < 0.0001$) at time $t = 30; 60; 120$ & 180 min

⇒ The air under the curve confirmed this ↓ in blood glucose levels ($p < 0.0001$) compared to UTC



Effect of *A. spinosus* on water and food intake per group



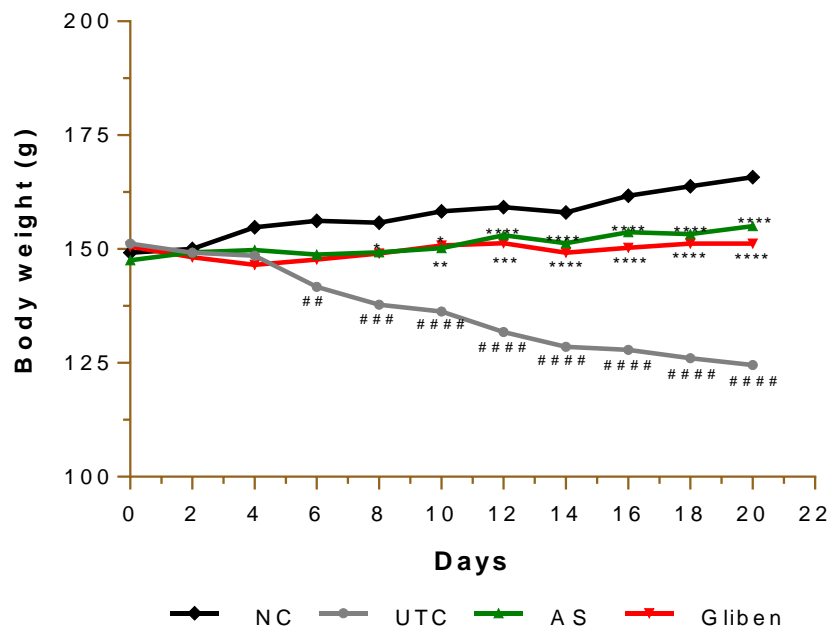
Treatment for 21 days :

⇒ Water & food intake ↑ ($p < 0.0001$) in untreated control group compared to NC (Figure A)

⇒ Water & food intake ↓ ($p < 0.0001$) in treated groups with *A. spinosus* 500 mg/kg & glibenclamide 0.6 mg/kg compared to UTC (Figure B)



Effect *A. spinosus* on changes in body weight



Treatment for 21 days :

⇒ Body weight ↓ ($p < 0.0001$) in untreated control group compared to NC

⇒ Body weight ↑ ($p < 0.0001$) in treated groups with *A. spinosus* 500 mg/kg & glibenclamide 0.6 mg/kg compared to UTC.



Effect of *A. spinosus* on the relative weight of organs

- ⇒ Brain
 - ⇒ Lungs
 - ⇒ Heart
 - ⇒ Liver
 - ⇒ Eyes
- No significant changes
- ⇒ Kidneys ↑ ($p < 0.01$) in UTC



Effect of *A. spinosus* on urinary parameters at the start and end of treatment

At the start of treatment

Glycosuria, ketonuria, proteinuria, hematuria leukocyturia => present
($p < 0.001$) in diabetes rats compared to NC

At the end of 21 days of treatment

⇒ Untreated control group

Glycosuria, ketonuria, proteinuria, hematuria leukocyturia => present
($p < 0.0001$)

⇒ Groups treated with *A. spinosus* 500 mg/kg & glibenclamide 0.6 mg/kg

Glycosuria, ketonuria, proteinuria, hematuria leukocyturia => absent
($p < 0.0001$)



Effect of *A. spinosus* on biochemical parameters at the start and end of treatment

At the start of treatment

serum creatinine; AST; CPK; triglycerides; total cholesterol; LDL-cholesterol => ↑ ($p < 0.001$) in diabetes rats compared to NC

At the end of 21 days of treatment

⇒ Untreated control group

- Serum urea; creatinine; AST; ALAT; CPK; triglycerides; LDL-cholesterol => ↑
- HDL-cholesterol => ↓

⇒ Groups treated with *A. spinosus* 500 mg/kg & glibenclamide 0.6 mg/kg

Serum urea; creatinine; CPK; triglycerides; LDL-cholesterol => ↓



Effect of *A. spinosus* on hematological parameters at the end of treatment

Untreated control group

- MCH; platelets; WBC; neutrophils => ↓ ($p < 0.001$)
- Lymphocytes => ↑ ($p < 0.01$) compared to NC

Groups treated with *A. spinosus* 500 mg/kg & glibenclamide 0.6 mg/kg

Platelets; lymphocytes => ↑ ($p < 0.01$)



Effect of *A. spinosus* in MDA & GSH content in the organs at the end of treatment

Untreated control group

- In the liver => MDA \uparrow ($p < 0.0001$) ; GSH \downarrow ($p < 0.01$)
- In the kidneys => MDA \uparrow ($p < 0.0001$) ; GSH \downarrow ($p < 0.01$)
- In the eyes => MDA \uparrow ($p < 0.0001$) ; GSH \downarrow ($p < 0.001$)

Groups treated with *A. spinosus* 500 mg/kg & glibenclamide 0.6 mg/kg

- In the liver => MDA \downarrow ($p < 0.0001$) ; GSH \uparrow ($p < 0.001$)
- In the kidneys => MDA \downarrow ($p < 0.0001$) ; GSH \uparrow ($p < 0.001$)
- In the eyes => MDA \downarrow ($p < 0.0001$) ; GSH \uparrow ($p < 0.01$)



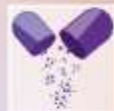Histopathological study after hematoxylin & eosin staining

Untreated group

- Kidneys => **glomerular sclerosis**
- Eyes => **macular edema**

Groups treated with *A. spinosus* 500 mg/kg & glibenclamide 0.6 mg/kg

- Kidneys => **normal**
- Eyes => **normal**



A. spinosus possessed bioactive compounds & ↓ significantly in oral glucose tolerance & in basal blood glucose levels of diabetes rats.

Our previous study => *A. spinosus* 125; 250 & 500 mg/kg b.w ↓ significantly ($p < 0.0001$) in ICR mice oral glucose tolerance & basal blood glucose levels (Atchou et al., 2020)

Others previous studies demonstrate antidiabetic activity of the leaves & whole plante of *A. spinosus* (Sangameswaran & Jayakar, 2008; Girija et al., 2011; Kumar et al., 2011; Bavarva & Narasimhacharya, 2013)



A. spinosus action in decreased in blood glucose levels was compared to glibenclamide => induction of insulin secretion & release (Rajasekaran et al., 2005; Pandarekandy, 2017).

In our previous study : *A. spinosus* induced in the presence of insulin,

⇒ no significant ↓ in blood glucose level of the chicken embryos *in ovo* at days 11

⇒ no significant ↑ in glucose uptake by muscles *ex vivo*

⇒ Confirmed intrapancreatic activity of *A. spinosus* (Lawson-Evi et al., 2020).



Administration of *A. spinosus* 500 mg/kg & glibenclamide offered protection against diabetes complications.

↓ in triglycerides; LDL-cholesterol & ↑ in HDL-cholesterol => correct dyslipidemia

↓ in CPK; LDL-cholesterol => protection against cardiovascular disease

↓ in ALAT; ASAT => hepatoprotection

↓ in uremia; creatinemia & disappearance of glucosuria, acetonuria, proteinuria, hematuria; leukocyturia => protection against diabetic nephropathy confirmed in histopathological *study*

↓ in MDA & ↑ in GSH; HDL-cholesterol => ↓ in inflammation & protection against retinopathy confirmed in histopathological study

↓ in lipoperoxidation (MDA) & in detoxification processes (GSH) => also protection against brain; lungs; heart; liver; eyes & kidneys cabled by hyperglycemia.



In our previous study : *A. spinosus* showed,

⇒ the antioxidant and reducing power (Atchou et al., 2020)

⇒ In diabetes, chronicle hyperglycemia => oxidative stress, which is an important factor in the onset of diabetes. Oxidative stress => ↑ ROS production which induce membrane lipids peroxidation, tissues & DNA damage, then accelerate the onset of complications of diabetes (Goldstein et al., 1996; Li et Shah, 2003; Povi et al., 2015).

⇒ ↓ in diabetes complications by *A. spinosus* => antioxidant & reducing activities



Conclusions

Evaluation of hydroethanolic extract *A. spinosus* roots in diabetes STZ SD rats for 21 days => ↓ in oral glucose tolerance & basal glucose levels. The mechanism of action of *A. spinosus* in blood glucose decreased was compared to glibenclamide by induction of insulin secretion and release from existing pancreatic β cells.

Treatment of diabetes STZ rats by *A. spinosus* => ↓ inflammation; ↓ membrane lipids peroxidation, ↑ detoxification processes & correct dyslipidemia ; thus protected against cardiovascular disease; nephropathy & retinopathy.

In this study, *A. spinosus* 500 mg/kg b.w can be used to treat T2DM and its complications related to oxidative stress. However, further studies are needed to elucidate all mechanism actions of extract, evaluate it toxicity & standardize the doses of extract in order to produce improve drugs.

