



Original Research Article (Experimental)

Polyphenol-rich fraction of *Parquetina nigrescens* mitigates dichlorvos-induced neurotoxicity and apoptosisGrace Onyeché Ochigbo^a, Adebowale Bernard Saba^a, Ademola Adetokunbo Oyagbemi^{a,*}, Temidayo Olutayo Omobowale^b, Ebunoluwa Racheal Asenuga^c^a Department of Veterinary Physiology, Biochemistry and Pharmacology, Faculty of Veterinary Medicine, University of Ibadan, Nigeria^b Department of Veterinary Medicine, Faculty of Veterinary Medicine, University of Ibadan, Nigeria^c Department of Veterinary Biochemistry, Faculty of Veterinary Medicine, University of Benin, Nigeria

ARTICLE INFO

Article history:

Received 14 June 2016

Received in revised form

2 September 2016

Accepted 21 September 2016

Available online 28 February 2017

Keywords:

Dichlorvos

Acetylcholinesterase

Apoptosis

Parquetina nigrescens

Antioxidant

ABSTRACT

Background: *Parquetina nigrescens* (Afzel.) Bullock of the family Asclepiadaceae is known for its anti-oxidant effects with wide range of uses in Southwestern Nigeria especially in traditional medicine. This study was undertaken to explore if polyphenol-rich fraction (prf) from *P. nigrescens* will ameliorate dichlorvos-induced neurotoxicity and apoptosis. The exploration utilized evaluation of markers of oxidative stress, apoptosis and serum acetylcholinesterase (AChE) levels.

Methods: Forty Wistar rats randomly placed in four groups were utilized for the study. Animals in Group A received corn oil, group B- dichlorvos (16 mg/kg), groups C and D- dichlorvos + 100 and 200 mg/kg prf of *P. nigrescens* respectively. Markers of oxidative stress, antioxidants and apoptosis were assessed in the serum and brain tissues using biochemical assay and immunohistochemistry.

Results: Exposure to dichlorvos caused significant decreases in AChE, catalase, superoxide dismutase, glutathione peroxidase (GPx) and increases in hydrogen peroxide (H₂O₂) generation and malondialdehyde levels. Histopathology and immunohistochemistry of the cerebellum and cerebrum of rats exposed to dichlorvos revealed greater neurotoxic effects in the cerebellum as well as decreased expressions of AChE with a concomitant increase in Bax (proapoptotic) compared to prf of *P. nigrescens* treated rats.

Conclusion: This study showed that dichlorvos caused cellular and tissue neurotoxicity by inhibiting AChE activity, induced oxidative stress and apoptosis in rats with prominent effects on the cerebellum than cerebrum. The prf of *P. nigrescens* showed amelioration of neurotoxicity by its antioxidative and antiapoptotic properties in rats exposed to dichlorvos.

© 2016 Transdisciplinary University, Bangalore and World Ayurveda Foundation. Publishing Services by Elsevier B.V. This is an open access article under the CC BY-NC-ND license (<http://creativecommons.org/licenses/by-nc-nd/4.0/>).

1. Introduction

Dichlorvos, a documented neurotoxic agent, is known to frequently affect non-target species including human [1]. The common use of dichlorvos in developing countries stems from its availability, affordability and most importantly, its efficacy. It is handled indiscriminately and used as a household insecticide in Nigeria especially Northern-Nigeria. Dichlorvos poisoning is more rampant in rural populace where agriculture thrives and these dwellers often store the chemical in and around their homes [2] as

well as use it in poorly ventilated areas. These predispose humans and other animals to exposure as non-target species. It causes acute and chronic neurotoxicity in humans and animals by its cholinesterase inhibiting ability. The commonly used organophosphate pesticide dichlorvos is known to cause neurologic lesions and this has been associated with lipid peroxidation in areas of the brain of rats. Besides the characteristic inhibition of cholinesterase, dichlorvos is reported to produce oxidative stress on acute exposure in human and animals [3] and treatment with antioxidants has been shown to repress the toxicity of dichlorvos either by preventing cholinesterase inhibition or/and by rapid reactivation of inhibited cholinesterases [4]. Dichlorvos intoxications are usually combated with atropine in West Africa although more often than not, no medical attention is given to patients and victims. However, the rural populace has the habit of using herbs for prophylaxis.

* Corresponding author.

E-mail address: aa.oyagbemi@ui.edu.ng (A.A. Oyagbemi).

Peer review under responsibility of Transdisciplinary University, Bangalore.

Parquetina nigrescens (Afzel.) Bullock, a perennial twine of the family Asclepiadaceae, has been commonly used in traditional medicine in Southwestern Nigeria as a component of medications for the treatment of various diseases [5]. Most of the heralded medicinal properties of this plant however, have not been scientifically substantiated. Results of various investigations however show correlation between its traditional uses and activities. Agbor and Odetola [6] reported a dose dependent increase in red blood cell count to affirm its use against anaemia. Its use in the treatment of diabetes has been substantiated by Saba et al. [7], while its antioxidant potential was reported by Akinrinmade and colleagues [8]. Studies on this plant show it contains folic acid, vitamin B₁₂ and anthraquinones. Its extracts contained flavonoids and antioxidant vitamins A and C [9] indicative of inherent antioxidant nutrients.

Although folk medicine has claimed the use of this plant in mitigating mental illnesses and other neurological conditions, there is paucity of data on its effect on dichlorvos-induced neurotoxicity and apoptosis. This study was aimed at investigating the possible use of the polyphenolic rich fraction of *P. nigrescens* to ameliorate dichlorvos-induced neurotoxicity.

2. Materials and methods

The study utilized the following materials through the processes and methods described below.

2.1. Chemicals

Acetylcholine iodide, 1,2-dichloro-4-nitrobenzene (CDNB), 5,5'-dithio-bis-2-nitrobenzoic acid (DTNB), trichloroacetic acid (TCA), thiobarbituric acid (TBA), glutathione, hydrogen peroxide (H₂O₂), sodium hydroxide, epinephrine, xylenol orange. Normal goat serum, Biotinylated antibody and Horse Radish Peroxidase (HRP) System was purchased from (KPL, Inc., Gaithersburg, Maryland, USA). Caspase 3 was purchased from Bioss Inc. Woburn, Massachusetts, USA, while 3, 3'-Diaminobenzidine (DAB) tablets were purchased from AMRESCO LLC. Ohio, USA. All other chemicals used were of analytical grade and obtained from British Drug Houses (Poole, Dorset, UK).

2.2. Plant collection and extraction

Freshly harvested aerial parts of *P. nigrescens* were collected within the premises of the University of Ibadan, Nigeria (December 2014) and identified at the herbarium in the University of Ibadan, Nigeria with voucher number UIH-22446. These were air dried and ground. The powder was then soaked in n-Hexane to defat for 24 h. It was then soaked in methanol for 72 h to obtain methanol crude extract, which was concentrated using a rotatory evaporator at 40 °C. The sticky residues were partitioned with chloroform to give chloroform soluble fractions. This was evaporated under reduced pressure and dried using an oven to obtain a polyphenol-rich fraction (prf).

2.3. Experimental design and animal treatment

Forty adult male Wistar rats weighing approximately 90–150 g were obtained from the Experimental Animal Unit of the Faculty of Veterinary Medicine, University of Ibadan and were randomly divided into 4 groups with 10 animals per group. The rats were maintained on commercial pelletized rats finisher feed and water was provided *ad libitum*. The animals were kept in plastic cages under controlled light cycle (12 h light/12 h dark).

Control group (group A) received corn oil while groups B, C and D received dichlorvos (16 mg/kg) only, dichlorvos + 100 mg/kg prf of *P. nigrescens* and dichlorvos + 200 mg/kg prf of *P. nigrescens* respectively. The prf of *P. nigrescens* was administered as a pre-treatment and dichlorvos at a sub-lethal (1/3LD50) dose. Dichlorvos was administered as a single oral gavage while other treatments lasted for 14 days. All animals were sacrificed at the end of the treatment period.

The animals were humanely cared for according to the criteria outline in the Guide for the Care and the Use of Laboratory Animals prepared by the National Academy of Science and published by the National Institutes of Health. During the experiment, ethics regulations were followed in accordance with national and institutional guidelines for the protection of the animal's welfare [10].

2.4. Blood sample collection and preparation of post-mitochondrial fraction

About 3 ml of blood was collected from the retro-orbital venous plexus of the animals into heparinized vials before they were sacrificed by cervical dislocation. The blood was centrifuged at 4,000 rpm for 15 min to obtain the serum. The cerebellum and cerebrum were harvested on ice, rinsed and homogenized in aqueous potassium buffer (0.1 M, pH 7.4) and the homogenate was centrifuged at 10,000 rpm (4°C) for 10 min to obtain the post-mitochondrial fraction.

2.5. Biochemical assays

AChE activity was assayed for in the plasma according to the method of Whittaker [11]. The post-mitochondrial fractions of the cerebellum and cerebrum were collected for the estimation of reduced GSH at 412 nm according to the method by Beutler et al. [12]. Protein concentration was determined by Biuret method as described by Gornal et al. [13]. Catalase activity was estimated using the method of Claiborne [14]. Glutathione-S-transferase was measured by the method of Habig et al. [15] and glutathione peroxidase (GPx) activity was determined as described by Rotruck et al. [16]. Superoxide dismutase was determined by measuring the inhibition of auto-oxidation of epinephrine at pH 10.2 as described by Misra & Fridovich [17] and with modification from our laboratory [18,19]. The MDA level was calculated as described by Varshney & Kale [20]. Lipid peroxidation in μmol MDA formed/mg protein was computed with a molar extinction coefficient of $1.56 \times 10^5 \text{ M}^{-1} \text{ cm}^{-1}$. H₂O₂ generation was estimated as described [21].

2.6. Histopathology

Small slices of cerebellum and cerebrum were collected in 10% buffered formalin for proper fixation. These tissues were processed and embedded in paraffin wax. 5–6 μm thick sections were made and stained with haematoxylin and eosin for histopathological examination [22].

2.7. Immunohistochemistry of AChE and Bax

Immunohistochemistry of paraffin embedded tissues of the cerebrum and cerebellum was performed after the tissues were obtained from buffered formalin perfused rats. The tissues were processed for immunohistochemistry based on the methods described by Todorich et al. [23]. Briefly, paraffin sections were melted at 60 °C in the oven. Dewaxing of the samples in xylene was followed by passage through ethanol of decreasing concentration (100–80%). Peroxidase quenching in 3% H₂O₂/methanol was

carried out with subsequent antigen retrieval performed by microwave heating in 0.01 M citrate buffer (pH 6.0) to boil. All the sections were blocked in normal goat serum (10%, HistoMark[®], KPL, Gaithersburg MD, USA) and probed with AchE antibody and Bax antibody (Abclonal[®]), 1:375 for 16 h in a refrigerator. Detection of bound antibody was carried out using biotinylated (goat anti-rabbit, 2.0 µg/ml) secondary antibody and subsequently, streptavidin peroxidase (Horse Radish Peroxidase-streptavidin) according to manufacturer's protocol (HistoMark[®], KPL, Gaithersburg MD, USA).

Reaction product was enhanced with diaminobenzidine (DAB, Amresco[®], USA) for 6–10 min and counterstained with high definition haematoxylin (Enzo[®], NY–USA), with subsequent dehydration in ethanol. The slides were covered with coverslips and sealed with resinous solution. The immunoreactive positive expression of AchE and Bax intensive regions were viewed starting from low magnification on each slice then with 400× magnifications using a photo microscope (Olympus) and a digital camera (Toupcam[®], Touptek Photonics, Zhejiang, China).

2.8. Statistical analysis

All values are expressed as mean ± standard deviation (SD). The test of significance between two groups was estimated by Student's t-test. One way Analysis of Variance (ANOVA) with Tukey's post-hoc test using GraphPad Prism 5.0 was also performed with p-Values < 0.05 considered statistically significant.

3. Results

3.1. Phytochemical analysis

The phytochemical analysis of *P. nigrescens* leaves revealed the presence of alkaloids, flavonoids, saponins and antraquinones. However, tannins, terpenoids and cardiac glycosides were absent.

3.2. Serum AchE activity

Exposure to dichlorvos caused a decrease in serum AchE activity in rats. No significant ($p < 0.05$) difference was recorded for rats in Group C but a significant increase in AchE activity was observed in Group D rats (Fig. 1) compared to control.

3.3. Antioxidant status in cerebellum and cerebrum

Exposure to dichlorvos produced significant ($p < 0.05$) decrease in catalase activity, GPx, glutathione-S-transferase and superoxide dismutase activity in the cerebellum (Table 1). Groups C and D treated with prf of *P. nigrescens* however, revealed lesser inhibition of these antioxidant enzymes (Table 1). In the cerebrum, the activities of catalase, GPx and superoxide dismutase decreased significantly when compared to the control (Table 2). However, the activity of cerebral glutathione-S-transferase increased significantly ($p < 0.05$) when compared to the control but was not statistically higher than the treated groups with prf of *P. nigrescens* (Table 2). The reduced glutathione and total thiol content were significantly reduced in rats exposed to dichlorvos with higher concentrations recorded for treated rats in both cerebellum and the cerebrum (Tables 3 and 4).

3.4. Oxidative stress markers in cerebellum and cerebrum

All groups exposed to dichlorvos showed significantly ($p < 0.05$) higher level of H₂O₂ generated in the cerebellum as opposed to control rats although lower levels were generated in

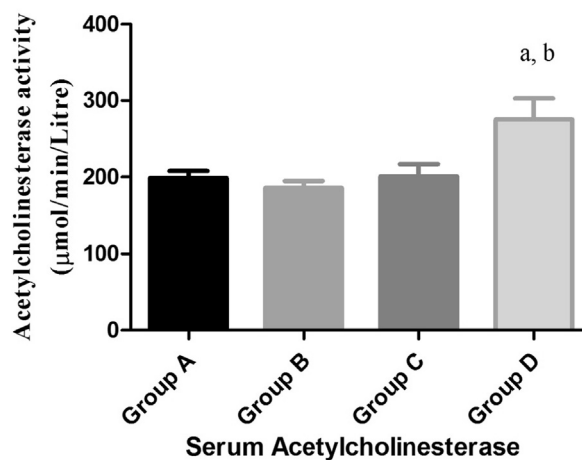


Fig. 1. Effect of prf of *P. nigrescens* on serum AchE activity of rats administered dichlorvos. Control group (group A) received corn oil while groups B, C and D received dichlorvos (16 mg/kg) only, dichlorvos + 100 mg/kg prf of *P. nigrescens* and dichlorvos + 200 mg/kg prf of *P. nigrescens* respectively. Superscript (a) indicates significant difference compared with control whereas superscript (b) indicates significant difference compared to dichlorvos alone. a, b = Significant difference at $p < 0.05$.

prf treated groups (Fig. 2). Similar alterations in H₂O₂ generation were observed in the cerebrum (Fig. 3). A significant ($p < 0.05$) increase in MDA formation (Fig. 4) accompanied by a decrease in nitric oxide (NO) (Fig. 6) was produced in the cerebellum of rats exposed to dichlorvos. The alterations in the cerebrum were similar in MDA formation (Fig. 5) and NO production (Fig. 7) but recorded greater levels compared to that in the cerebellum.

3.5. Histopathology and immunohistochemistry

The controls had no visible pathology while rats exposed to dichlorvos showed chromatolysis of Purkinje cells and high cellular infiltration in the cerebellum (Fig. 12). The cerebrum of these rats showed hypercellularity of the cortex and increased vascularisation (Fig. 13). Mild to moderate cellular infiltration in the cerebellum was observed in prf treated rats exposed to dichlorvos (Fig. 12). Immunohistochemistry of the cerebellum and cerebrum of rats exposed to dichlorvos showed lower AchE and higher Bax expression relative to the control. Evidence of recovery is evident with higher AchE and lower Bax expressions by prf treated rats exposed to dichlorvos (Figs. 8–11).

4. Discussion

Organophosphorus poisoning owes its clinical signs mainly to the accumulation of acetylcholine at cholinergic synapses due to the inhibition of AchE activity and subsequent impairment of neuromuscular transmission. However, in groups treated with prf of *P. nigrescens*, higher levels of AchE activity was observed indicative of lesser neurotoxic effects on the rats.

A decrease in antioxidant enzymes (SOD, CAT, GPx and GST) compared to the control was observed in the cerebellum and cerebrum of rats exposed to dichlorvos. This is in agreement with Guvenç et al. [24] who reported the induction of oxidative stress with dichlorvos toxicity. In the cerebellum of rats treated with 100 mg/kg prf of *P. nigrescens*, a significant increase in SOD compared to the toxicant group was observed with concomitant increases in CAT and GPx activity. SOD as a first line of

Table 1
Effect of prf of *P. nigrescens* on cerebellar antioxidant enzymes of rats (n = 5).

Experimental groups	Group A	Group B	Group C	Group D
CAT	101.52 ± 7.58	33.57 ± 3.80 ^a	151.13 ± 6.37 ^{a,b}	94.97 ± 5.75 ^b
GPx	64.77 ± 0.73	58.72 ± 1.13 ^a	60.60 ± 1.22 ^{a,b}	58.50 ± 1.11 ^a
GST	79.0 ± 0.01	69.3 ± 0.01 ^a	74.6 ± 0.00	61.9 ± 0.01 ^a
SOD	13.39 ± 0.08	11.51 ± 0.32 ^a	12.25 ± 0.27 ^{a,b}	11.46 ± 0.21 ^a

Control group (group A) received corn oil while groups B, C and D received dichlorvos (16 mg/kg) only, dichlorvos + 100 mg/kg prf of *P. nigrescens* and dichlorvos + 200 mg/kg prf of *P. nigrescens* respectively. Superscript (a) indicates significant difference compared with control whereas superscript (b) indicates significant difference compared to dichlorvos alone. a, b = Significant difference at $p < 0.05$.

CAT (Catalase; mmol H₂O₂ consumed/min/mg protein); GPx (Glutathione peroxidase; units/mg protein); GST (Glutathione-S-transferase; mmol 1-chloro-2,4-dinitrobenzene-GSH complex formed/min/mg protein); SOD (Superoxide Dismutase; units/mg protein).

Table 2
Effect of prf of *P. nigrescens* on cerebral antioxidant enzymes of rats (n = 5).

Experimental groups	Group A	Group B	Group C	Group D
CAT	48.55 ± 5.90	43.13 ± 2.92	57.51 ± 5.92 ^{a,b}	46.82 ± 5.06
GPx	52.30 ± 1.26	47.16 ± 0.86 ^a	47.28 ± 1.90 ^a	47.87 ± 0.89 ^a
GST	101.2 ± 0.02	128.5 ± 0.01 ^a	143.0 ± 0.01 ^{a,b}	158.3 ± 0.01 ^{a,b}
SOD	0.44 ± 0.00	0.39 ± 0.02 ^a	0.40 ± 0.01 ^a	0.40 ± 0.01 ^a

Control group (group A) received corn oil while groups B, C and D received dichlorvos (16 mg/kg) only, dichlorvos + 100 mg/kg prf of *P. nigrescens* and dichlorvos + 200 mg/kg prf of *P. nigrescens* respectively. Superscript (a) indicates significant difference compared with control whereas superscript (b) indicates significant difference compared to dichlorvos alone. a, b = Significant difference at $p < 0.05$.

CAT (Catalase; mmol H₂O₂ consumed/min/mg protein); GPx (Glutathione peroxidase; units/mg protein); GST (Glutathione-S-transferase; mmol 1-chloro-2,4-dinitrobenzene-GSH complex formed/min/mg protein); SOD (Superoxide Dismutase; units/mg protein).

Table 3
Effect of prf of *P. nigrescens* on cerebellar glutathione and total thiol content of rats (n = 5).

Experimental groups	Group A	Group B	Group C	Group D
GSH	47.14 ± 0.36	45.97 ± 0.70 ^a	45.40 ± 0.63 ^a	45.11 ± 0.80 ^a
T-Thiol	54.3 ± 0.00	30.6 ± 0.01 ^a	45.3 ± 0.00 ^{a,b}	28.0 ± 0.00 ^a

Control group (group A) received corn oil while groups B, C and D received dichlorvos (16 mg/kg) only, dichlorvos + 100 mg/kg prf of *P. nigrescens* and dichlorvos + 200 mg/kg prf of *P. nigrescens* respectively. Superscript (a) indicates significant difference compared with control whereas superscript (b) indicates significant difference compared to dichlorvos alone. a, b = Significant difference at $p < 0.05$.

GSH (Reduced glutathione; μmol/mg protein); T-Thiol (Total Thiol; μmol/mg protein).

Table 4
Effect of prf of *P. nigrescens* on cerebral glutathione and total thiol content of rats.

Experimental groups	Group A	Group B	Group C	Group D
GSH	50.17 ± 0.15	49.37 ± 1.08 ^a	49.70 ± 0.60 ^a	48.64 ± 0.76 ^a
T-Thiol	32.5 ± 0.00	24.7 ± 0.00 ^a	29.0 ± 0.00 ^{a,b}	26.8 ± 0.00 ^a

Control group (group A) received corn oil while groups B, C and D received dichlorvos (16 mg/kg) only, dichlorvos + 100 mg/kg prf of *P. nigrescens* and dichlorvos + 200 mg/kg prf of *P. nigrescens* respectively. Superscript (a) indicates significant difference compared with control whereas superscript (b) indicates significant difference compared to dichlorvos alone. a, b = Significant difference at $p < 0.05$.

GSH (Reduced glutathione; μmol/mg protein); T-Thiol (Total Thiol; μmol/mg protein).

antioxidant defense dismutates superoxide anion radical to H₂O₂ while CAT and GPx catalyse subsequent conversion of H₂O₂ to water and oxygen. In the cerebrum, a similar decrease in antioxidant enzymes compared to control was observed on a lesser magnitude with an exception in GST levels of the treatment groups compared to the control. This could be attributed to an adaptive mechanism to cope with neurotoxicity. The activity of SOD in the cerebrum was lower when compared to the cerebellum and this might justify lesser neurotoxic effect of dichlorvos in the cerebellum. The lower the amount of superoxide anions, the lesser the activity of SOD, as the redox status of

that tissue is not greatly tampered with. GST is responsible for the detoxification of xenobiotics and the increase in its activity may suggest a development of an adaptive response to rid the body of oxidative stress [25]. There was a significant reduction in the GSH levels of the cerebrum and cerebellum in all treatment groups compared to controls. This could be attributed to conjugation with electrophiles produced following dichlorvos administration and/or the decreased activities of enzymes responsible for the regeneration of GSH such as GPx and glutathione reductase [26]. It could also be traced to the utilization of GSH as a substrate and co-factor in the proper functioning of GPx and GST.

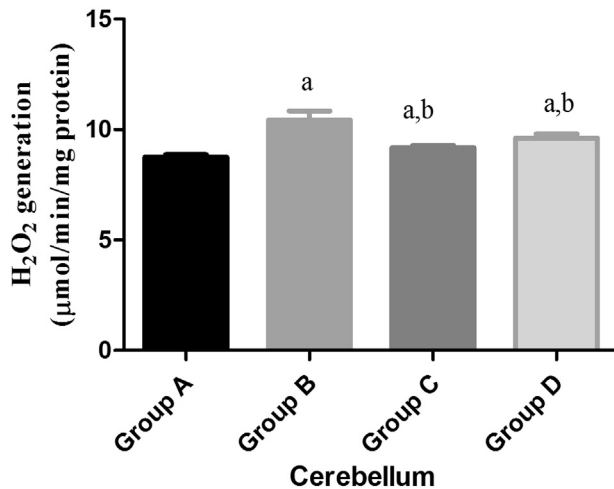


Fig. 2. Effect of prf of *P. nigrescens* on H₂O₂ generation in the cerebellum of rats. Control group (group A) received corn oil while groups B, C and D received dichlorvos (16 mg/kg) only, dichlorvos + 100 mg/kg prf of *P. nigrescens* and dichlorvos + 200 mg/kg prf of *P. nigrescens* respectively. a, b = Significant difference at $p < 0.05$.

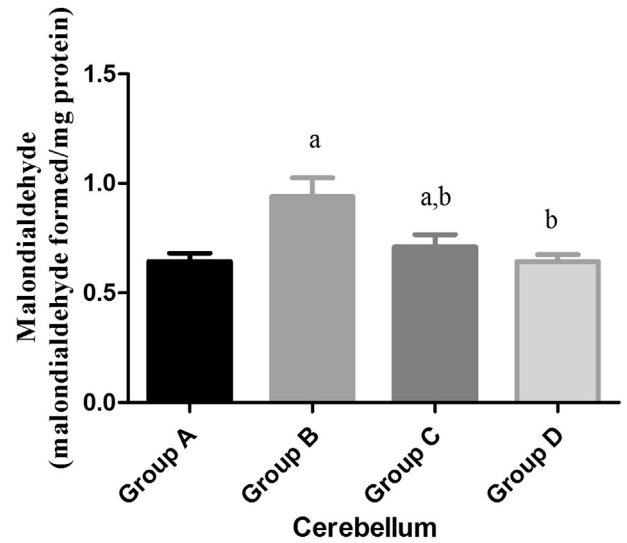


Fig. 4. Effect of prf of *P. nigrescens* on Malondialdehyde formation in the cerebellum of rats. Control group (group A) received corn oil while groups B, C and D received dichlorvos (16 mg/kg) only, dichlorvos + 100 mg/kg prf of *P. nigrescens* and dichlorvos + 200 mg/kg prf of *P. nigrescens* respectively. a, b = Significant difference at $p < 0.05$.

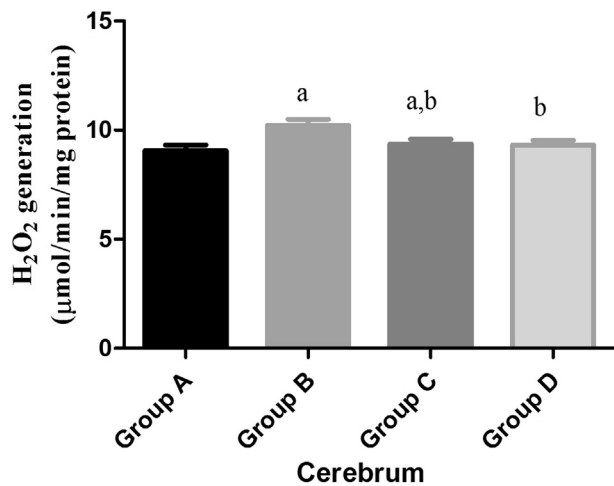


Fig. 3. Effect of *P. nigrescens* on H₂O₂ generation in the cerebrum of rats. Control group (group A) received corn oil while groups B, C and D received dichlorvos (16 mg/kg) only, dichlorvos + 100 mg/kg prf of *P. nigrescens* and dichlorvos + 200 mg/kg prf of *P. nigrescens* respectively. a, b = Significant difference at $p < 0.05$.

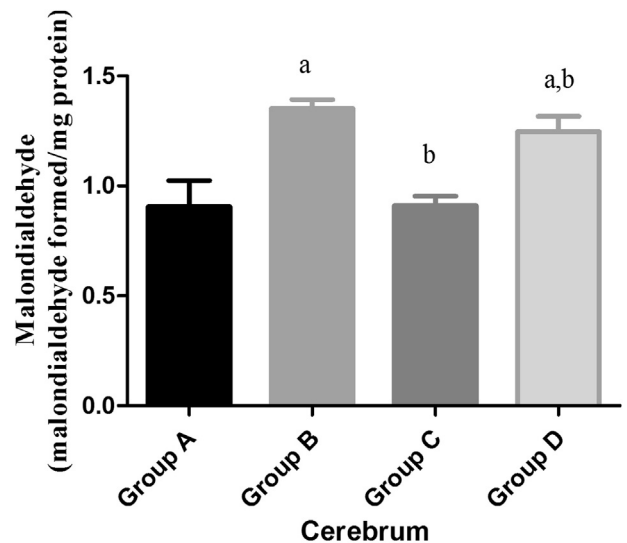


Fig. 5. Effect of prf of *P. nigrescens* on Malondialdehyde formation in the cerebrum of rats. Control group (group A) received corn oil while groups B, C and D received dichlorvos (16 mg/kg) only, dichlorvos + 100 mg/kg prf of *P. nigrescens* and dichlorvos + 200 mg/kg prf of *P. nigrescens* respectively. a, b = Significant difference at $p < 0.05$.

Previous research recorded lowered GSH levels post exposure to dichlorvos and lindane in rat brain [26], together with dichlorvos and monocrotophos in rats [27]. The exposure to dichlorvos brings about neurotoxicity which is in part linked to reactive oxygen species (ROS) production and oxidative stress [2]. The prf of *P. nigrescens* possessing antioxidant properties, ameliorated oxidative stress thereby protecting the nervous tissues and ameliorated dichlorvos-induced neurotoxicity as evident by the results in this study.

Pesticides are considered as agents that cause lipid peroxidation, increase the production of ROS which leads to an increased generation of oxidative stress. There was significantly higher generation of H₂O₂ and production of MDA in the

cerebellum and cerebrum of all groups exposed to dichlorvos as compared to the control group. This evidence of lipid peroxidation points to the susceptibility of the brain to oxidative stress due to its high oxygen consumption ability and rich possession of polyunsaturated fatty acids. However, groups treated with prf of *P. nigrescens* showed significantly lower levels of H₂O₂ generation and MDA formed which is suggestive of its antioxidant capacity in both the cerebellum and cerebrum. Various reports have shown the amelioration of dichlorvos-induced neurotoxicity by agents with antioxidant activities [1,28].

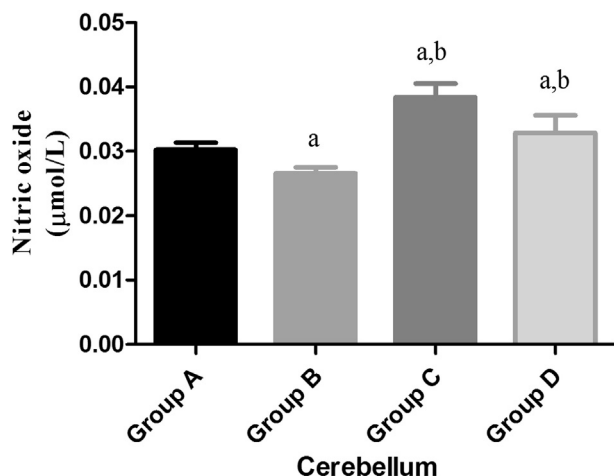


Fig. 6. Effect of prf of *P. nigrescens* on cerebellum NO levels of rats. Control group (group A) received corn oil while groups B, C and D received dichlorvos (16 mg/kg) only, dichlorvos + 100 mg/kg prf of *P. nigrescens* and dichlorvos + 200 mg/kg prf of *P. nigrescens* respectively, a, b = Significant difference at $p < 0.05$.

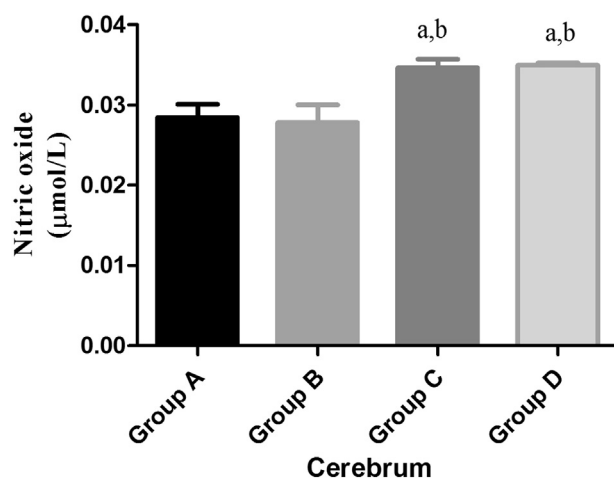


Fig. 7. Effect of *P. nigrescens* on NO levels in the cerebrum of rats. Control group (group A) received corn oil while groups B, C and D received dichlorvos (16 mg/kg) only, dichlorvos + 100 mg/kg prf of *P. nigrescens* and dichlorvos + 200 mg/kg prf of *P. nigrescens* respectively, a, b = Significant difference at $p < 0.05$.

NO levels in both the cerebellum and cerebrum were significantly higher in rats treated with prf of *P. nigrescens* compared to both control group and those exposed to dichlorvos alone. Following AchE inhibition by dichlorvos exposure, acetylcholine accumulation is hypothesized to activate glutamatergic neurons leading to activation of nitric oxide synthase (increased NO production) by NMDA receptor activation [2]. Lower levels of NO in cerebellum and cerebrum of rats exposed to dichlorvos alone in this study, may be attributed to a possible reaction with superoxide anion radical available from a decreased scavenging activity of SOD under the stress condition. This reaction leads to the formation of a very toxic peroxynitrite which causes oxidative stress mediated cell damage [29].

The cerebellum of rats exposed to dichlorvos alone showed severely lowered expression of AchE which agrees with the

mechanism of action of dichlorvos. AchE expressions similar to the control were observed in prf of *P. nigrescens* treated rats in a dose-dependent manner. This is suggestive of a protective effect of the prf of *P. nigrescens* against dichlorvos-induced neurotoxicity. However, in the cerebrum, inhibition of AchE was not as prominent as that in the cerebellum as was evident by a considerable expression observed in the group exposed to dichlorvos alone. Nonetheless, it showed a lesser expression compared to that in the treated groups. A higher inhibition of AchE in the cerebellum compared to the cerebrum is in agreement with the clinical signs and symptoms of dichlorvos-induced neurotoxicity such as involuntary tremors and incoordination. The cerebellum controls motor movement and coordinates voluntary movements leading to a poised muscular activity.

Histopathological examination of the cerebellum of rats exposed to dichlorvos alone revealed Purkinje cells showing chromatolysis as well as a high amount of cellular infiltrations pointing to severe inflammatory activities. This cellular degeneration of Purkinje cells in the cerebellum points to a compromised function in motor information processing because it is a vital constituent in synaptic information transmission. The increased cellular infiltrations indicate an inflammatory condition which could be attributed to lipid peroxidation which triggers cellular infiltration [30]. In the cerebrum of rats exposed to dichlorvos, there was hypercellularity of the cerebral cortex and increased vascularisation especially at microcirculation. Cerebrum of rats treated with prf of *P. nigrescens* showed no obvious lesions on histopathological examination with slides showing normal neutrophils and neurons similar to that of the control. This is evidence of an ameliorative and possibly neuroprotective effect of the prf of *P. nigrescens*.

The expression of the pro-apoptotic protein (Bax) was highest in the cerebellum of rats administered dichlorvos. This is suggestive that dichlorvos can induce programmed cell death. Sun-karia et al. [31] reported increase expressions of bax in dichlorvos treated rats and that the Bcl-2 family proteins played an essential role in neuronal cell death and disturbances in the regulation of these proteins aggravate ischaemic neuronal injury [32]. Studies by Slotkin et al. have pinpointed that pro-apoptotic are part of the cholinesterase-unrelated effects underlying organophosphorus neurotoxicities [33]. Also, oxidative stress can trigger apoptosis in cells through mitochondria dependent and independent pathways [34]. ROS interact with biomolecules in the body such as proteins, DNA and lipids leading to structural and functional alterations which lead to a cellular redox change that can trigger apoptosis. ROS attack neurons and glial cells of the brain due to the high lipid content of the brain leading to neuronal injury and damage that lead to apoptosis. The decreased expression of Bax in rats treated with prf of *P. nigrescens* thus is suggestive of its attenuating effect on apoptosis and neuronal injury. The expression of Bax in the cerebrum of rats exposed to dichlorvos was generally lower than that observed in the cerebellum. This may be indicative of lesser effects of dichlorvos in the cerebrum compared to the cerebellum.

5. Conclusion

This study showed that dichlorvos caused cellular and tissue neurotoxicity by inhibiting AchE activity, induced oxidative stress and apoptosis in rats with prominent effects on the cerebellum than cerebrum. It also indicated the ability of prf of *P. nigrescens* to ameliorate dichlorvos-induced neurotoxicity, oxidative stress and apoptosis in rats.

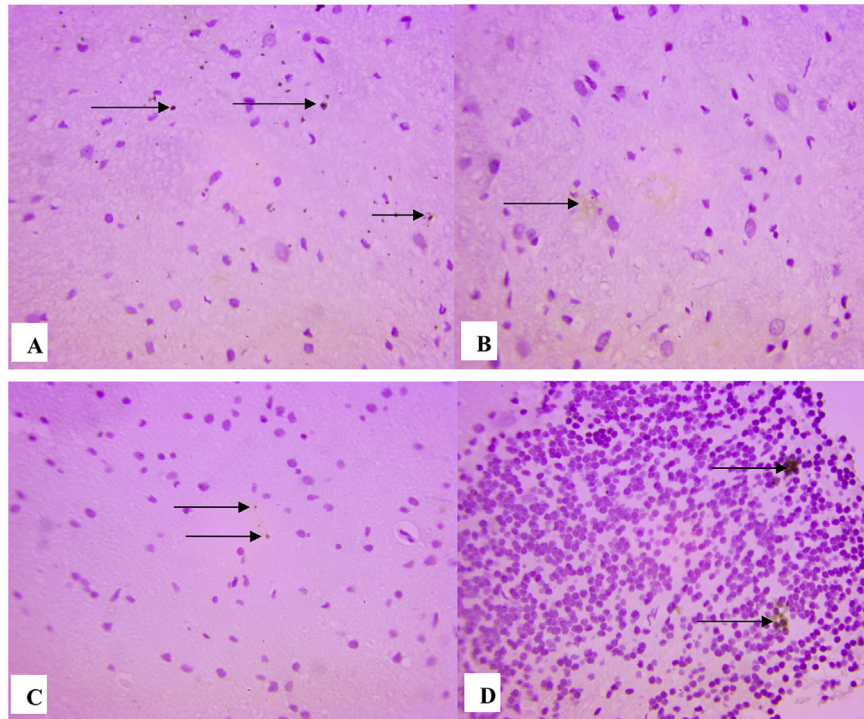


Fig. 8. Immunohistochemistry of AchE in the cerebellum of rats. A – Control: shows positive and high expression of AchE; B – Dichlorvos (16 mg/kg) alone: shows lower expression of AchE than control; C – 100 mg/kg prf of *P. nigrescens* + dichlorvos: shows higher expression of AchE similar to control; D – 200 mg/kg prf of *P. nigrescens* + dichlorvos: shows higher expression of AchE similar to control. The slides were counterstained with high definition haematoxylin and viewed 400× objectives.

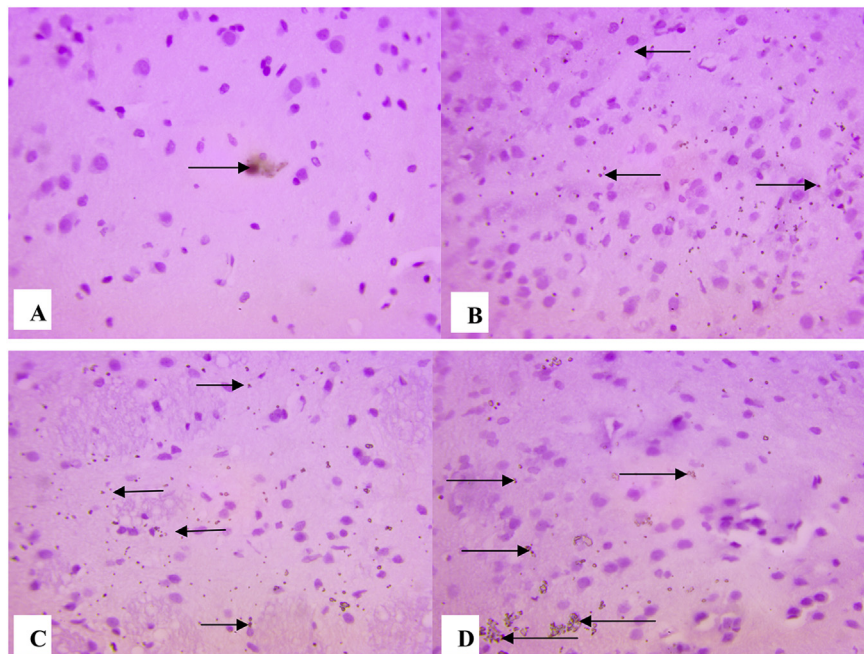


Fig. 9. Immunohistochemistry of AchE in the cerebrum of rats. A – Control: shows positive and high expression of AchE; B – Dichlorvos (16 mg/kg) alone: shows lower expression of AchE than control; C – 100 mg/kg prf of *P. nigrescens* + dichlorvos: shows higher expression of AchE similar to control; D – 200 mg/kg prf of *P. nigrescens* + dichlorvos: shows higher expression of AchE similar to control. The slides were counterstained with high definition haematoxylin and viewed 400× objectives.

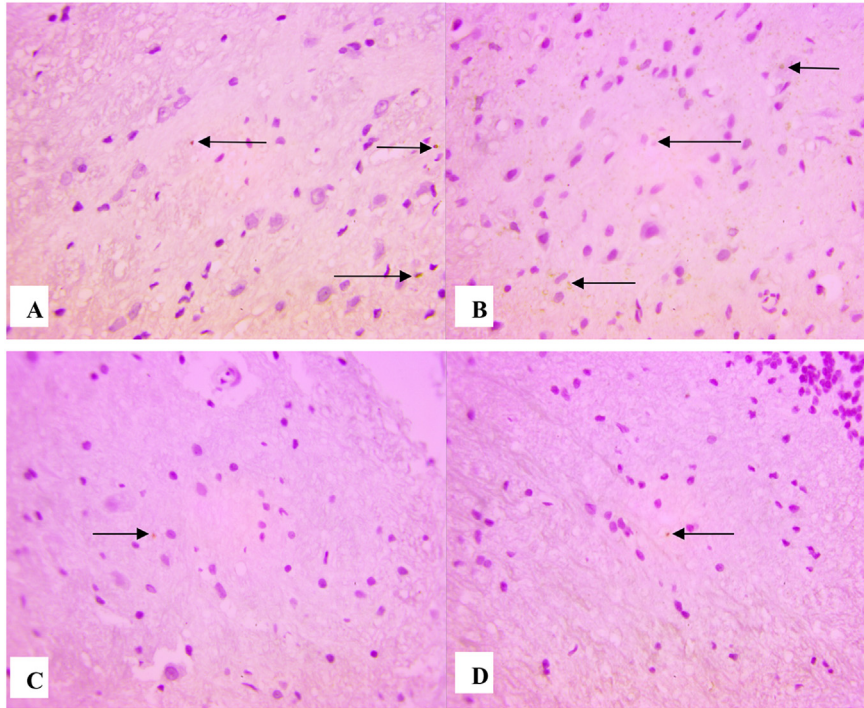


Fig. 10. Immunohistochemistry of BAX (pro-apoptotic antigen) in the cerebellum of rats. A – Control: shows positive and low expression of BAX; B – Dichlorvos (16 mg/kg) alone: shows higher expression of BAX than control; C – 100 mg/kg prf of *P. nigrescens* + dichlorvos: shows lower expression of BAX similar to control; D – 200 mg/kg prf of *P. nigrescens* + dichlorvos: shows lower expression of BAX similar to control. The slides were counterstained with high definition haematoxylin and viewed 400× objectives.

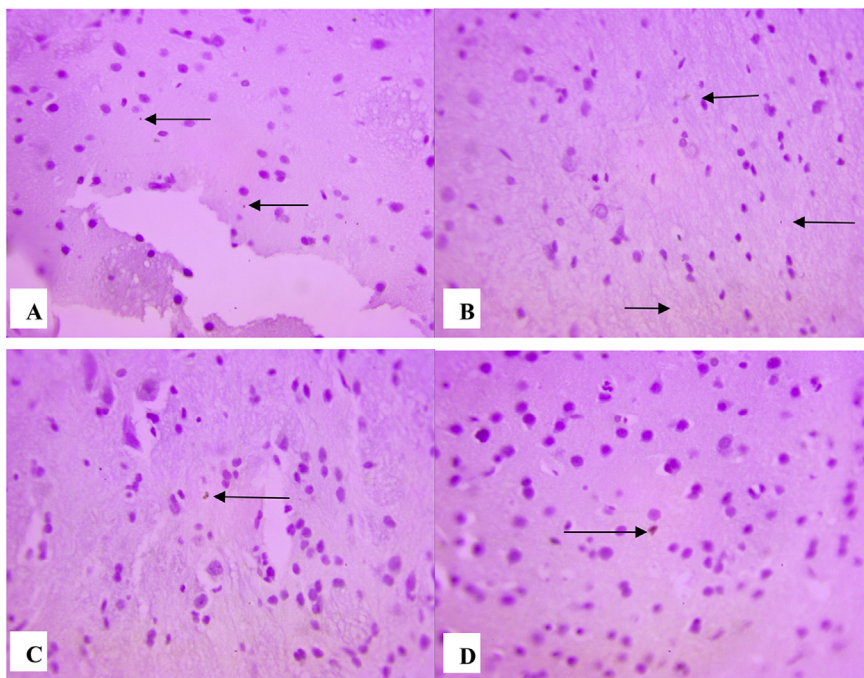


Fig. 11. Immunohistochemistry of BAX (pro-apoptotic antigen) in the cerebrum of rats. A – Control: shows positive and low expression of BAX; B – Dichlorvos (16 mg/kg) alone: shows higher expression of BAX than control; C – 100 mg/kg prf of *P. nigrescens* + dichlorvos: shows lower expression of BAX similar to control; D – 200 mg/kg prf of *P. nigrescens* + dichlorvos: shows lower expression of BAX similar to control. The slides were counterstained with high definition haematoxylin and viewed 400× objectives.

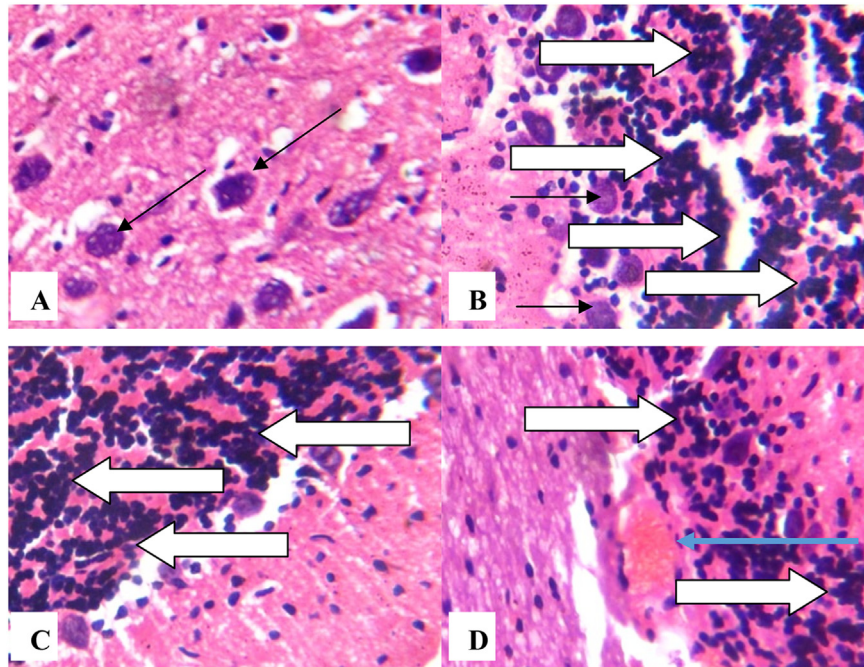


Fig. 12. Photomicrograph showing cerebellum of rats. (A) – Control: Normal Purkinje cells (black arrows) and granular layer; (B) – Dichlorvos (16 mg/kg): Chromatolysis of Purkinje cells (black arrows), (B), (C) – 100 mg/kg prf of *P. nigrescens* + dichlorvos; and (D) – 200 mg/kg prf of *P. nigrescens* + dichlorvos: with high, moderate and mild cellular infiltrations respectively (white arrows) and mild haemorrhage in (D) (blue arrow). Plates are stained with H and E stains and viewed with 400× objectives.

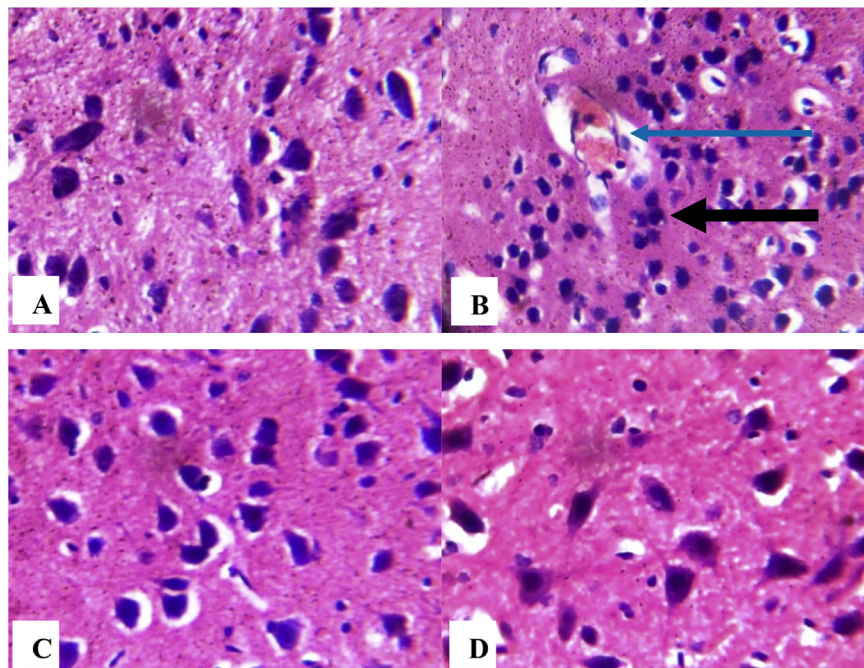


Fig. 13. Photomicrograph showing cerebrum of rats (A) – Control: with normal hippocampal formation, neutrophils and neurons; (B) administered with dichlorvos (16 mg/kg) shows hypercellularity of cerebral cortex (black arrow) and increased vascularisation especially at microcirculation (blue arrow); (C) and (D) treated with prf of *P. nigrescens* (100 mg/kg and 200 mg/kg respectively) shows normal neutrophil, neurons and hippocampal formation. Plates are stained with H and E stains and viewed with 400× objectives.

Conflict of interest

We wish to confirm that there are no known conflicts of interest associated with this publication and there has been no significant financial support for this work that could have influenced its outcome.

References

- [1] Srivastava A, Shivanandappa T. Differential cholinesterase inhibition in the rat brain regions by dichlorvos and protective effect of *Decalepis hamiltonii* roots. *Neurotoxicol* 2011;32:931–4.
- [2] Binukumar BK, Gill KD. Cellular and molecular mechanisms of dichlorvos neurotoxicity: cholinergic, noncholinergic, cell signaling, gene expression and therapeutic aspects. *Indian J Exp Biol* 2010;48:697–709.
- [3] Soltaninejad K, Abdollahi M. Current opinion on the science of organophosphate pesticides and toxic stress: a systematic review. *Med Sci Monit* 2009;15:RA75–90.
- [4] Buyukokuroglu ME, Cemek M, Yurumez Y, Yavuz Y, Aslan A. Antioxidative role of Melatonin in organophosphate toxicity in rats. *Cell Biol Toxicol* 2008;24:151–8.
- [5] Makanjuola OY, Dada OE, Akharaiyi FC. Antibacterial potentials of *Parquetina nigrescens* extracts on some selected pathogenic bacteria. *J Nat Prod* 2010;3:124–9.
- [6] Agbor AG, Odetola AA. Hematological studies of *Parquetina nigrescens* on haemorrhagic anaemic rats. *Afr J Med Med Sci* 2001;30(1–2):105–9.
- [7] Saba AB, Oyagbemi AA, Azeez OL. Antidiabetic and haematonic effects of *Parquetina nigrescens* on alloxan induced type-1 diabetes and normocytic normochromic anaemia in Wistar rats. *Afr Health Sci* 2010;10(3):276–82.
- [8] Akinrinmade FJ, Akinrinde AS, Soyemi OO, Oyagbemi AA. Antioxidant potential of the methanol extract of *Parquetina nigrescens* mediates protection against intestinal ischemia-reperfusion injury in rats. *J Diet Suppl* 2016;13(4):420–32.
- [9] Imaga NA, Gbenle GO, Okochi VI, Adenekan S, Duro-Emmanuel T, Oyeniyi B, et al. Phytochemical and antioxidant nutrient constituents of *Carica papaya* and *Parquetina nigrescens* extracts. *Sci Res Essays* 2010;5(16):2202–18.
- [10] PHS (Public Health Service). Public health service policy on humane care and the use of laboratory animals. Washington, DC: US Department of Health and Humane Services; 1996. p. 99–158.
- [11] Whittaker M. Cholinesterases. In: Bergmeyer HU, editor. *Methods of enzymatic analysis*. 3rd ed. Weinheim: Verlag Chemie; 1984. p. 52–63.
- [12] Beutler EO, Duron B, Kelly M. Improved method for the determination of blood glutathione. *J Lab Clin Med* 1963;61:882–8.
- [13] Gornal AG, Bardawill JC, David MM. Determination of serum proteins by means of Biuret reaction. *J Biol Chem* 1949;177:751–66.
- [14] Claiborne A. Catalase activity. In: Greenwald RA, editor. *Handbook of methods for oxygene radical research*. Boca Raton, FL: CRC Press; 1985. p. 283–4.
- [15] Habig WH, Pabst MJ, Jacoby WB. Glutathione-S-transferase activity: the enzymic step in mercapturic acid formation. *J Biol Chem* 1974;249:130–9.
- [16] Rotruck JT, Pope AL, Ganther HE, Swanson AB, Hafeman DG, Hoekstra WG. Selenium: biochemical role as a component of glutathione peroxidase. *Sci* 1973;179:588–90.
- [17] Misra HP, Fridovich I. The role of superoxide anion in the autooxidation of epinephrine and a simple assay for superoxide dismutase. *J Biol Chem* 1972;247:3170–5.
- [18] Omobowale TO, Oyagbemi AA, Akinrinde AS, Saba AB, Daramola OT, Ogunpolu BS, et al. Failure of recovery from lead induced hepatotoxicity and disruption of erythrocyte antioxidant defence system in Wistar rats. *Environ Toxicol Pharmacol* 2014;37:1202–11.
- [19] Oyagbemi AA, Omobowale TO, Akinrinde AS, Saba AB, Ogunpolu BS, Daramola O. Lack of reversal of oxidative damage in renal tissues of lead acetate-treated rats. *Environ Toxicol* 2015;30:1235–43.
- [20] Varshney R, Kale RK. Effect of calmodulin antagonists on radiation induced lipid peroxidation in microsomes. *Int J Biol* 1990;158:733–41.
- [21] Woff SF. Ferrous ion oxidation in the presence of ferric ion indicator xylenol orange for measurement of hydrogen peroxides. *Methods Enzymol* 1994;233:182–9.
- [22] Drury RA, Wallington EA, Cancerson R. *Carlton's histopathological techniques*. 4th ed. Oxford/London/New York: Oxford University Press; 1976.
- [23] Todorich B, Olopade JO, Surguladze N, Zhang X, Neely E, Connor JR. The mechanism of vanadium-mediated developmental hypomyelination is related to destruction of oligodendrocyte progenitors through a relationship with ferritin and iron. *Neurotox Res* 2011;19(3):361–73.
- [24] Guvenç D, Aksoy A, Kursad Y, Atmaca E, Yavuz O. 3-nitrotyrosine levels in dichlorvos-induced neurotoxicity. *Arh Hig Rada Toksikol* 2014;65:109–12.
- [25] Oruc EO, Ust D. Evaluation of oxidative stress responses and neurotoxicity potential of diazinon in different tissues of *Cyprinus carpio*. *Environ Toxicol Pharmacol* 2007;23(1):48–55.
- [26] Sharma P, Singh R. Dichlorvos and lindane induced oxidative stress in rat brain: protective effects of ginger. *Pharm Res* 2012;4(1):27–32.
- [27] Dwivedi N, Bhutia YD, Kumar V, Yadav P, Kushwaha P, Swarnkar H, et al. Effects of combined exposure to dichlorvos and monocrotophos on blood and brain biochemical variables in rats. *Hum Exp Toxicol* 2010;29:121–9.
- [28] Suke SG, Ahmed RS, Pathak R, Tripathi AK, Banerjee BD. Attenuation of phosphamidon-induced oxidative stress and immune dysfunction in rats treated N-acetylcysteine. *Braz J Med Biol Res* 2008;41:765–8.
- [29] Komolafe K, Olaleye TM, Seeger RL, Carvalho FB, Boligon AA, Athayde ML, et al. *Parkia biglobosa* improves mitochondrial functioning and protects against neurotoxic agents in rat brain hippocampal slices. *Biomed Res Int* 2014;326290. <http://dx.doi.org/10.1155/2014/326290>. 2014.
- [30] Uttara B, Singh AV, Zamboni P, Mahajan RT. Oxidative stress and neurodegenerative diseases: a review of upstream and downstream antioxidant therapeutic options. *Curr Neuropharmacol* 2009;7(1):65–74.
- [31] Sunkaria A, Wani WY, Sharma DR, Gill KD. Dichlorvos exposure results in activation induced apoptotic cell death in primary rat microglia. *Chem Res Toxicol* 2012;25(8):1762–70.
- [32] Ma Y, Li Y, Zhang C, Zhou X, Wu Y. Neuroprotective effect of 4-methylcyclopentadecanone on focal cerebral ischemia/reperfusion injury in rats. *J Pharm Sci* 2014;125:320–8.
- [33] Slotkin TA, Oliver CA, Seidler FJ. Critical periods for the role of oxidative stress in the developmental neurotoxicity of chlorpyrifos and terbutaline, alone or in combination. *Brain Res Dev Brain Res* 2005;157:172–80.
- [34] Sinha K, Das J, Pal PB, Sil PC. Oxidative stress: the mitochondria-dependent and mitochondria-independent pathways of apoptosis. *Arch Toxicol* 2013;87(7):1157–80.